Volume 31 Number 10
OCTOBER 2008 SUPPLEMENT TO
www.ORTHOSuperSite.com

ORTHOPEDICS®

A SLACK Incorporated® Publication

Expertise in Orthopedic Navigation

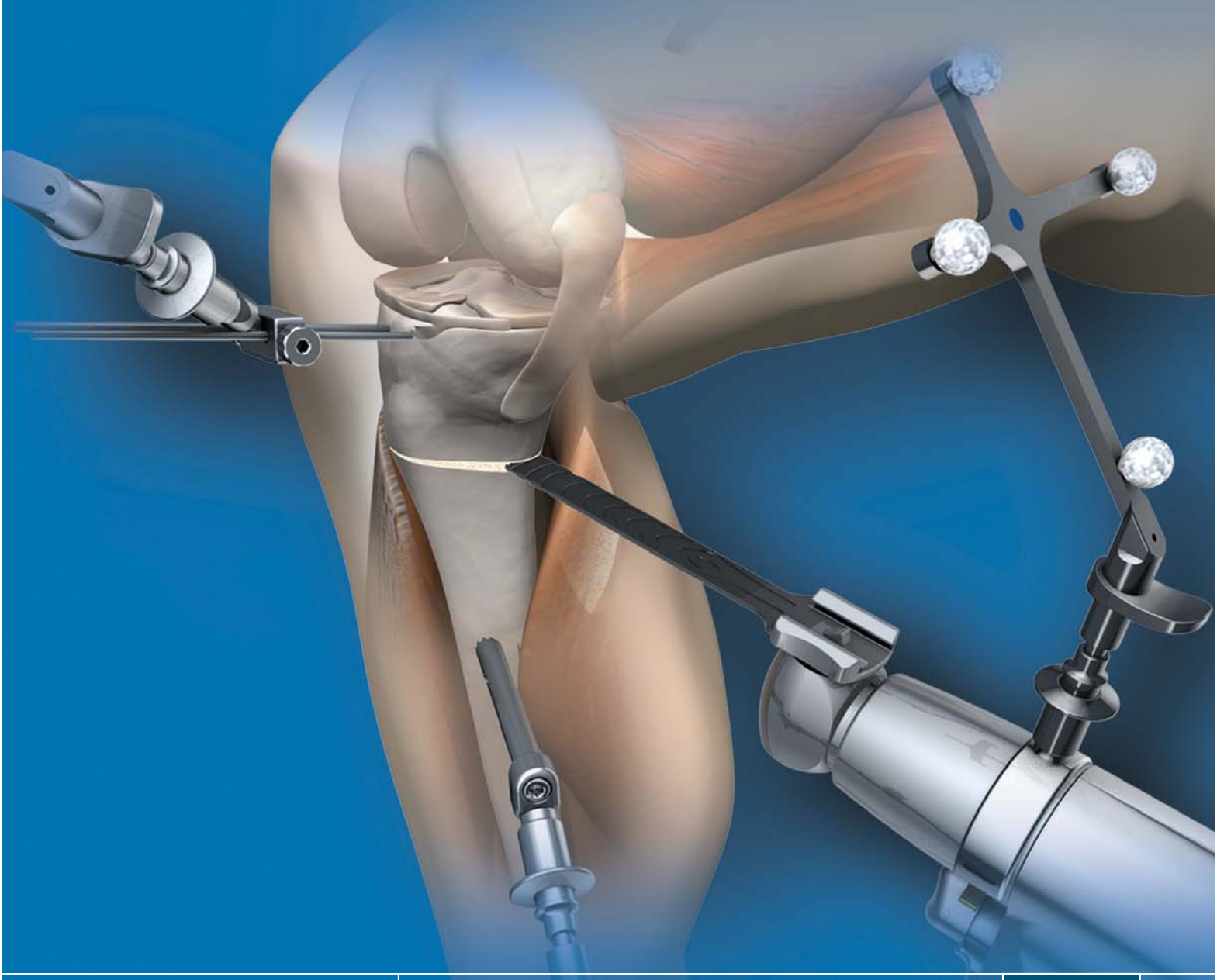

SLACK INCORPORATED

Sponsored as an educational service by B. Braun Aesculap

CITED IN MEDLINE

Volume 31 Number 10 • OCTOBER 2008/SUPPLEMENT

A SLACK Incorporated® Publication

ORTHOPEDICS®

Expertise in Orthopedic Navigation

Dear Colleague:

Precise measurements and clear identification of bony landmarks are key to successful orthopedic surgery. The use of computer-assisted navigation, especially in minimally invasive surgery, maintains clear visibility during procedures, allowing the surgeon to obtain accurate measurements necessary for positioning implants in total hip arthroplasty (THA) and total knee arthroplasty (TKA).

This supplement contains articles that explore the accuracy of computer-assisted navigation used for THA and TKA. Topics include navigation-guided gap technique, as well as nonimage-guided, infrared optical, electromagnetic, and three-dimensional navigation. Other topics include managing limb length discrepancy and restoring offset, predicting postoperative function, and assessing notch geometry for accurate tunnel placement.

I would like to thank the contributors for their participation in this ORTHOPEDICS supplement and the sponsor, B. Braun Aesculap, for its support.

Robert D'Ambrosia, MD
Editor-in-Chief, ORTHOPEDICS

Publisher: ORTHOPEDICS® (ISSN 0147-7447, Canadian BN-129780466RT) is published monthly by SLACK Incorporated, 6900 Grove Rd, Thorofare, NJ 08086-9447. Telephone: (856) 848-1000; fax (856) 848-6091; e-mail: ortho@slackinc.com; World Wide Web: http://www.ORTHOSuperSite.com. Printed in the USA.

Subscriptions: Subscription requests should be addressed to the publisher. Annual Subscription price is: Individual, One year–$109.00. Residents/fellows: $60.00; letter of qualification from medical school must accompany order. All subscriptions, without exception, will start with the first issue published after the order is received. Back copies are available, but must be purchased separately. Cost per individual copy is $32.00. All orders for individual or back issues must be accompanied by payment. Permission requests to copy or reuse material published herein should be addressed to publishingpermissions@slackinc.com. All requests for reprint orders and prices should be addressed to John Kain, SLACK Incorporated, 6900 Grove Road, Thorofare, NJ 08086; 856-848-1000. Authorization to photocopy items for internal or personal use, or the internal or personal use of specific clients, is granted by SLACK Incorporated, provided the fee of $.25 per page per copy is paid directly to Copyright Clearance, 222 Rosewood Dr, Danvers, MA 01923. This consent does not extend to other kinds of copying, such as for general distribution, resale, advertising and promotional purposes, or for creating new collective works.

Change of Address: If you have not been receiving your monthly issues of ORTHOPEDICS due to a change of address, please advise the appropriate association of your new address. ORTHOPEDICS uses these lists for mailing monthly issues to physicians who qualify. Membership is not required. For MDs, write: American Medical Association, Dept of Physician Biographic Records, 515 N State St, Chicago, IL 60610. For DOs, write: American Osteopathic Association, Membership Services, 142 E Ontario St, Chicago, IL 60611. **For subscribers only:** Notice should be sent to the publisher six weeks in advance of effective date. Include old and new addresses with zip codes. The publisher cannot accept responsibility for undelivered copies. Periodicals Postage Paid at Thorofare, New Jersey 08086-9447 and at additional mailing offices. **POSTMASTER:** Send address changes to SLACK Incorporated, 6900 Grove Road, Thorofare, NJ 08086-9447.

Indexed in: Medline/PubMed, EBSCO, ProQuest, Ovid, EMBASE, Science Citation Index, Current Contents/Clinical Medicine, CINAHL, BioEngineering Abstracts, CAB Abstracts, Calcium & Calcified Tissue Abstracts, Health & Safety Sciences Abstracts, Physical Education Index, SCOPUS.

Volume 31 Number 10 • OCTOBER 2008/SUPPLEMENT

A SLACK Incorporated® Publication

ORTHOPEDICS®

feature articles

A SLACK Incorporated® Publication

ORTHOPEDICS®

SLACK INCORPORATED
Delivering the best in health care information and education worldwide
6900 GROVE ROAD
THOROFARE, NJ 08086-9447
PHONE: 856-848-1000
FAX: 856-848-6091
ORTHO@SLACKINC.COM

ORTHOSuperSite.com

A SLACK Incorporated® Publication

ORTHOPEDICS®

Navigated and Nonnavigated Total Hip Arthroplasty: Results of Two Consecutive Series Using a Cementless Straight Hip Stem

DIDIER MAINARD, MD

abstract

The purpose of this study was to compare conventional and navigated technique and a recently developed straight hip stem for uncemented primary total hip arthroplasty. The results of two consecutive implantation series of 42 patients (nonnavigated) and 42 patients (navigated) were analysed for implant positioning and complications. All surgeries were performed by the investigator. Radiographic analysis of cup position showed a significant improvement with reduced radiologic inclination (53° nonnavigated /44° navigated; $P < .001$) and higher anteversion (7° nonnavigated /12° navigated; $P < .001$). The mean postoperative limb length difference was 6.2 mm (SD, 9.0 for nonnavigated) and 4.4 mm (SD, 6.4 for navigated). Intraoperative and early postoperative complications were not different. No dislocation occurred in either group. There was one intraoperative trochanter fracture that was not revised (nonnavigated) and one revision because of a periprosthetic fracture caused by fall down during rehabilitation (navigated). We conclude that acetabular implant positioning can be significantly improved by the use of navigated surgery technique. The data for postoperative limb length difference were still similar but within the expected range in both groups. The effect of improved cup positioning on mid- and long-term results for both groups has to be investigated further.

Cementless total hip arthroplasty (THA) should lead to survival rates of > 95% at 10 years.[1] Implant positioning of cup and stem components may influence long-term results, and early results can be improved by reducing postoperative complications due to impingement,[2] joint dislocation[3], or wear and acetabular component failure.[4] The definition of appropriate implant positioning of THA components may be controversial and is always influenced by individual patient circumstances. Preoperative planning considers indication, bone morphology, and the degree of joint destruction to position the implant components. Cementless implants must be fixed with appropriate primary stability and should adjust limb length discrepancies. Cup positioning must have a positive anteversion value of 10º to 20º and an average inclination of 40º to 45º without extreme flat inclinations (<35º) or extreme high inclination (>55º). The radiographic evaluation of implant positions is difficult due to projection and magnification errors. Pelvic ante- or retroversion[5] or different femoral rotation[6] and flexion may lead to deviations of projected implant positions.

In conventional implantation technique, surgeons experience has a major influence on preoperative plan and intraoperative implementation. Navigated THA implantation technique is an intraoperative tool to assist the surgeon with data on implant positioning for the implementation of a surgical plan to achieve an optimal implant position for the individual patient. Because the investigator is currently using routine THA navigation the purpose of the study was to compare implant positioning and short-term complications in two consecutive cementless THA implantation series without and with the use of this navigation technology.

MATERIAL AND METHODS

In 2000, we introduced a recently developed straight cementless hip stem

Dr. Mainard is from Centre Hospitalier Universitaire Nancy, France.

ORTHOPEDICS was unable to determine whether Dr. Mainard has any relevant financial relationships to disclose or whether they are paid consultants for any companies.

Correspondence should be addressed to Didier Mainard, MD, Department for Orthopedics and Traumatology, CHU Nancy, France; didier.mainard@ciril.fr.

Figure 1: Straight cementless hip stem.

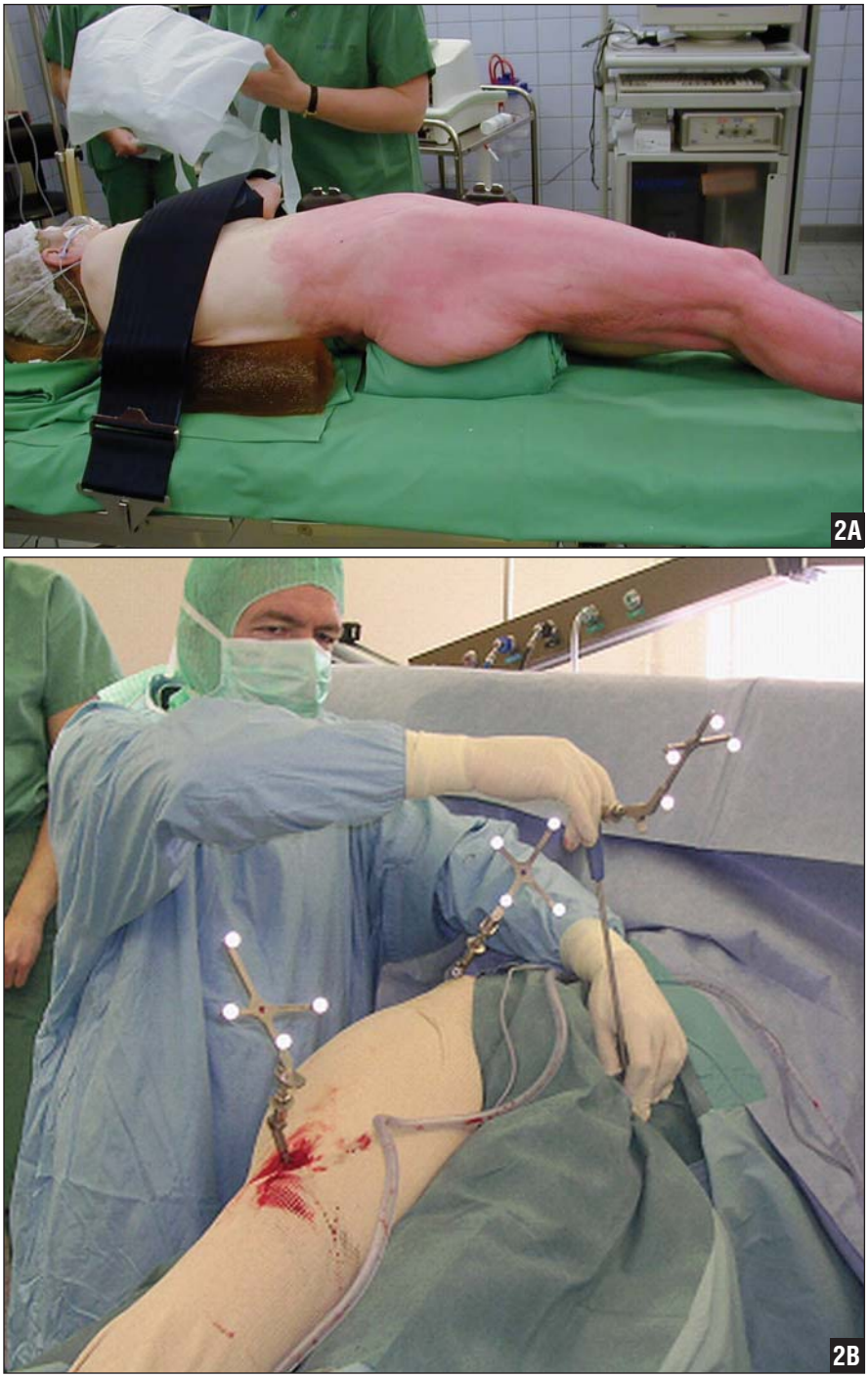

Figure 2: A, Semilateral decubitus patient position of 30° to 45° for a direct lateral THA approach registration of the anterior pelvic plane. B, Pointer registration of the anterior pelvic plane.

(Excia; B. Braun Aesculap, Tuttlingen, Germany) that had been designed for primary THA (Figure 1). We introduced THA navigation technology (OrthoPilot; B. Braun Aesculap) for cup (2005) and stem (2006) positioning. The registration of the anterior pelvic plane is performed with a pointer, and a distal femoral fixation of the navigation sensor is used.

Two consecutive implantation series of 42 THAs with appropriate postoperative radiograph projections in non-navigated technique (April 2000 to December 2001) and 42 THAs in navigated technique (September 2006 to December 2007) were compared. The group of 42 navigated patients was retrospectively included backward from December 2007. All 84 surgeries were performed by the investigator. Implant position was evaluated on postoperative anteroposterior radiography between 2 and 3 months after the index surgery. All pelvic radiographs were made in strict standing position of the patient. The operated hip joints were classified on the preoperative radiographs into three subgroups: group 1 with a preoperative leg shortening (>5 mm), group 2 with a preoperative leg length equality (±5 mm), and group 3 with preoperative lengthening of the operated leg (>5 mm). Additionally, the projected values of the caput collum diaphysis (CCD) angle were classified into three subgroups (<125º, 125º to 135º, and >135°). Changes in leg length were measured using the most distal line between the teardrop figure and the proximal corner of the lesser trochanter as anatomical landmarks.[7] The distance between the two teardrops and the head diameter of the hip replacement was used to scale preoperative

Table 1

General patient data for the two groups

	Nonnavigated group	Navigated group	Comparability
Number of THAs	n = 42	n = 42	
Operating period	April 2000 to Dec 2001	Sept 2006 to Dec 2007	
CCD (Ø / SD)	127° / SD = 10.5°	130° / SD = 8.8°	P =.16
Age at THA (y)	60.5 / SD = 11.8	63.3 / SD = 14.1	P = .04*
BMI	27.3 / SD = 4.4	28.1 / SD = 7.2	P = .90
Operated leg	22 of 42 right	21 of 42 right	P = .83
Gender	53% men	43% men	P = .16
Indication	86% Primary osteoarthritis	88% Primary osteoarthritis	P = .67

**Data is different because P .05 (Mann-Whitney U test).*

Table 2

Pre- and postoperative results for leg length difference and absolute lengthening values for the operated hip joint

	Ø Preoperative leg length difference to the nonoperated hip	Ø Leg lengthening of the operated hip	Ø Postoperative leg length difference to the nonoperated hip
Ø Nonnavigated	-2.3 mm (SD 7.3)	9.1 mm (SD 6.2)	6.2 mm (SD 9.0)
Ø Navigated	-5.5 mm (SD 7.2)	8.5 mm (SD 5.4)	4.4 mm (SD 6.4)

and postoperative radiographs. Radiographic cup positions were also measured for inclination in relation to the teardrop line. Anteversion was calculated with the method of Pradhan.[8] All THA surgeries were performed with a direct lateral approach with the patient in semilateral decubitus position of 30º to 45º (Figure 2a). A distal pin with an infrared sensor on the femur was used for the femoral reference (Figure 2b). The navigated THAs were performed using a minimally invasive surgical technique. Intraoperative and postoperative complications were documented, and all patients achieved immediate postoperative full-load bearing, which was possible without pain.

Results

The general data for the two groups are comparable according to the Mann-Whitney *U* test for the nonparametrical values (CCD angle, age, BMI) and the chi-square test for the distribution of the operated leg, gender, and indication. All values are summarized in Table 1. Patients age at time THA showed a statistical difference because the *P* value was slightly below .05.

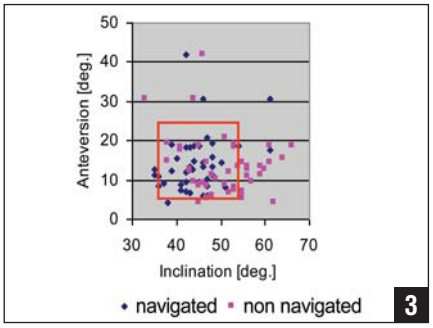

Figure 3: Safe zone result for radiographic cup position (navigated/non-navigated).

Cup Positioning

Radiographic analysis of cup position showed a significant difference. Radiologic inclination (53°: SD, 8.1 [non-navigated]; 44°: SD, 5.6 [navigated]; $P < .001$) was reduced by an average of 8° by the use of navigation. The radiologic anteversion (7°: SD, 4.6 [non-navigated]; 12°: SD, 5.3 [navigated]; $P < .001$) was increased by 6°. The number of cup positions within a safe zone definition of radiographic inclination/anteversion of 45°/15°±10° (Figure 3) was also significantly improved by navigation (21 of 42, 50% non-navigated /38 of 42, 90% navigated; $P < .001$).

Leg Length

Independent of the preoperative circumstance, the postoperative values for the change of the limb length of the operated hip were not significantly different (Mann-Whitney *U* test $P = .7$) and showed a mean leg lengthening of 9.2 mm (SD, 6.2 mm for non-navigated) and 8.5 mm (SD, 5.4 for navigated). Considering also the preoperative leg length difference, the resulting postoperative leg length difference was 6.2 mm (SD, 9.0) in the non-navigated group and 4.4 mm (SD, 6.4) in the navigated group (Table 2).

Dependant of the preoperative classification of preexisting leg length difference the values for navigated and nonnavigated

Table 3

Average leg lengthening for the operated hip side

Preoperative leg length difference	< - 5 mm	±5 mm	>5 mm
Ø Leg lengthening THA side (nonnavigated)	+6.3 mm (n = 11)	+10.7 mm (n = 24)	+7.6 mm (n = 4)
Ø Leg lengthening THA side (navigated)	+10.2 mm (n = 22)	+7.6 mm (n = 17)	-1.4 mm (n = 2)

Table 4

Average leg lengthening for different preoperative values of femoral CCD angle

Preoperative CCD angle	<125°	125°-135°	>135°
Ø Leg lengthening (non-navigated)	+9.0 mm	+11.0 mm	+3.3 mm
Ø Leg lengthening (navigated)	+10.8 mm	+8.0 mm	+7.4 mm

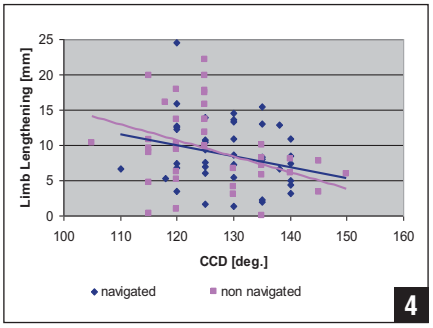

Figure 4: Matched graph of preoperative CCD angle and postoperative leg lengthening (navigated /non-navigated).

procedures showed a slight decrease of intraoperative leg lengthening in the navigated technique (Table 3).

The matched graph of the preoperative CCD angle and the results of leg lengthening showed a trend of increased leg lengthening for smaller CCD angles (Figure 4).

The classified values of leg lengthening within the three groups of preoperative CCD angles, however, did not reflect this tendency (Table 4).

Complications

There were no implant related or navigation technology related complications. There were no joint dislocations in both groups. One intraoperative trochanter fracture was treated with a cerclage (non-navigated). One revision was caused by a periprosthetic fracture after fall down during rehabilitation (navigated).

Discussion

The comparison of patient groups in navigated and non-navigated THA technique is a possible method to obtain additional information about the benefits and the possible improvement of implant positioning. This study design has general limitations because the measurement of implant position on radiograph is less precise than CT-based measurements. Our measurements of radiologic inclination and anteversion were taken in a straight standing position with anteroposterior radiographs, which should not exceed a deviation of 5 mm compared with CT.[9] Our mean limb length data of the not operated hip joint were also small (+1.3 mm nonnavigated and -1.3 mm navigated). The method of cup position measurements can be improved if the radiograph is taken while the patient is in a standing position. Here the preoperative flexion contraction is reduced as it is during postoperative rehabilitation in the first weeks after THA.[10]

The comparison of two nonrandomized implantation series operated by a single surgeon might include a certain bias but can exclude the influence of different surgical techniques. Our non-navigated patient group is under continuous clinical and radiographic follow-up to document the mid- and long-term results of our cementless straight hip stem, which was developed when THA navigation for the hip stem was not available. The retrospective definition of the navigated patient group represents our current surgical procedure with this implant. Our results show a very clear and significant improvement of acetabular cup positioning by the use of THA navigation. Therefore, we also support the use of the anterior plane reference[11] for THA navigation.

Our results do not clearly show a change of leg lengthening data using navigated or non-navigated technique. In our two series, the average total limb lengthening of the operated hip joint was below 10 mm (9.2 mm non-navigated and 8.5 mm navigated) and therefore below a value of clinical relevance[12] and well comparable with other studies with mean lengthening of 7 mm.[13] Postoperative limb discrepancy after THA has been analyzed with the same radiographic technique as in our study[14] in 408 cases with 97% <10 mm and 86% <6 mm. Using a templating technique,[15] the mean postoperative limb discrepancy was 3.9 mm in a series of 420 cases. Our result of a mean limb length discrepancy is comparable with this data and is close to a level of 5 mm (6.2 mm non-navigated and 4.4 mm navigated).

"Unexpected" postoperative leg length discrepancies can be reduced, for example, by using mechanical devices[16] or intraoperative radiograph.[17] This should also be the case for THA navigation technology. A navigation system generally

records the absolute intraoperative lengthening between pelvis and femur. The aspect of limb length discrepancy/equalization to the contralateral hip joint has to be considered preoperatively. We aim for a minimum intraoperative leg lengthening of 4 to 5 mm in cases of primary osteoarthritis to compensate for cartilage destruction. The "tendency" to lengthen the leg to increase stability is less common because the head diameters have increased. In our navigated series, we used 32-mm heads compared with 28-mm components in the earlier nonnavigated series, which did not influence the dislocation rate. The larger head size might explain the tendency of slightly smaller values for intraoperative leg lengthening in the navigated series. On the other hand, the navigated series had a higher preoperative limb length discrepancy (-5.5 mm) compared with the nonnavigated group (-2.3 mm). Our explanation for the similar values in leg length discrepancy in both series is certain intraoperative inconsistencies due to the distal femoral reference of the used navigation software. This aspect leads to an intraoperative decision for leg lengthening independent of the available navigation data. We know today that a femoral referencing closer to the hip joint or even a pinless femoral referencing leads to more accurate data for limb length and femoral offset changes. The significant improvement of cup positioning encourages us to continue our navigated THA procedure, and we will investigate additional improved navigation workflows for intraoperative limb lengthening and offset data.

References

1. Hallan G, Lie SA, Furnes O, Engesaeter LB, Vollset SE, Havelin LI. Medium- and long-term performance of 11,516 uncemented primary femoral stems from the Norwegian arthroplasty register. *J Bone Joint Surg Br*. 2007; 89(12):1574-1580.
2. Malik A, Maheshwari A, Dorr LD. Impingement with total hip replacement. *J Bone Joint Surg Am*. 2007; 89(8):1832-1842.
3. Joshi A, Lee CM, Markovic L, Vlatis G, Murphy JC. Prognosis of dislocation after total hip arthroplasty. *J Arthroplasty*. 1998; 13(1):17-21.
4. Shon WY, Baldini T, Peterson MG, Wright TM, Salvati EA. Impingement in total hip arthroplasty a study of retrieved acetabular components. *J Arthroplasty*. 2005; 20(4):427-435.
5. Babisch JW, Layher F, Amiot LP. The rationale for tilt-adjusted acetabular cup navigation. *J Bone Joint Surg Am*. 2008; 90(2):357-365.
6. Eckrich SG, Noble PC, Tullos HS. Effect of rotation on the radiographic appearance of the femoral canal. *J Arthroplasty*. 1994; 9(4):419-426.
7. Goodman SB, Adler SJ, Fyhrie DP, Schurman DJ. The acetabular teardrop and its relevance to acetabular migration. *Clin Orthop Relat Res*. 1988; (236):199-204.
8. Pradhan R. Planar anteversion of the acetabular cup as determined from plain anteroposterior radiographs. *J Bone Joint Surg Br*. 1999; 81(3):431-435
9. Sabharwal S, Zhao C, McKeon JJ, McClemens E, Edgar M, Behrens F. Computed radiographic measurement of limb-length discrepancy. Full-length standing anteroposterior radiograph compared with scanogram. *J Bone Joint Surg Am*. 2006; 88(10):2243-2251.
10. Kiefer H, Othman A. The Orthopilot navigation system for primary Bicontact total hip replacement. *Z Orthop Unfall*. 2007; 145 (suppl 1):S49-S52.
11. Mayr E, Kessler O, Prassl A, Rachbauer F, Krismer M, Nogler M. The frontal pelvic plane provides a valid reference system for implantation of the acetabular cup: spatial orientation of the pelvis in different positions. *Acta Orthop*. 2005; 76(6):848-853.
12. Maloney WJ, Keeney JA. Leg length discrepancy after total hip arthroplasty. *J Arthroplasty*. 2004; 19(4 suppl 1):108-110.
13. Goldstein WM, Gordon A, Branson JJ. Leg length inequality in total hip arthroplasty. *Orthopedics*. 2005; 28(9 suppl):S1037-S1040.
14. Woolson ST, Hartford JM, Sawyer A. Results of a method of leg-length equalization for patients undergoing primary total hip replacement. *J Arthroplasty*. 1999; 14(2):159-164.
15. Iagulli ND, Mallory TH, Berend KR, Lombardi AV Jr, Russell JH, Adams JB, Groseth KL. A simple and accurate method for determining leg length in primary total hip arthroplasty. *Am J Orthop*. 2006; 35(10):455-457.
16. Matsuda K, Nakamura S, Matsushita T. A simple method to minimize limb-length discrepancy after hip arthroplasty. *Acta Orthop*. 2006; 77(3):375-379.
17. Hofmann AA, Bolognesi M, Lahav A, Kurtin S. Minimizing leg-length inequality in total hip arthroplasty: use of preoperative templating and an intraoperative radiograph. *Am J Orthop*. 2008; 37(1):18-23.

Comparative Study of Acetabular Center Axis vs Anterior Pelvic Plane Registration Technique in Navigated Hip Arthroplasty

SAM HAKKI, MD; LUIS DORDELLY, BS; J. DANIEL OLIVEIRA, MD

abstract

There is significant variation in registering the anterior pelvic plane (APP) among experienced navigated hip arthroplasty surgeons, reflecting negatively on the accuracy of determining inclination and anteversion. Whether it is variation in pelvic anatomy or improper positioning, this inaccuracy emphasizes the need for alternative methods of registration, of which the acetabular center axis (ACA) is proposed. Data collected from ACA and APP registration were compared with postoperative computed tomography (CT) images of the pelvis in 34 cases. Findings showed ACA software to be comparable with CT in its accuracy in determining the inclination and version angles of the acetabulum and cup implant.

Currently, the anterior pelvic plane (APP) is used to identify the cup and acetabular orientation when navigating total hip arthroplasty (THA). First described by Cunningham[1] in 1922, the APP is based on the two anterior superior iliac spines (ASIS) and the two pubic tubercles. Recently, Jaramaz et al[2] have introduced the APP concept to computer-assisted cup placement in hip arthroplasty, and it has proved to be a useful tool.[3] However, the reliability of APP registration as a reference system in a lateral decubitus position[4,5] is jeopardized because the contralateral ASIS is not readily accessible with either a pointer or the ultrasound methods.[6] Furthermore, variation in thickness of subcutaneous tissue, the movement during the registration process, and the anatomic variations of acetabular version among healthy individuals resulted in major errors in cup orientation.[7]

To address these concerns, we postulate that the acetabular center axis (ACA) software is patient-specific, independent of variations in anatomy or pelvic position, and relies on readily accessible anatomic landmarks of the acetabulum rather than the anterior pelvic plane points. In this CT-based study, the reliability of ACA in determining acetabular anteversion and inclination angles is compared with that of the APP in computer navigation of THA.

MATERIALS AND METHODS

This prospective study compares, through postoperative pelvis CT, the ACA registration with that of APP using anterolateral intermuscular mini-invasive computer assisted THA. Of the 36 prospective patients enrolled, 2 were excluded for lack of complete data. Patient age ranged from 34 to 83 years (mean, 63 years), and 31 patients were men. Twenty-six had primary osteoarthritis, and 8 had avascular necrosis. Mean body mass index was 29.2 kg/m^2. Twenty-six percent of patients had dysplastic acetabulum, whereas 15% were protrusio.

The APP registration was done by palpation of both the ASIS and symphysis pubis at equal distance from the skin with the patient in the lateral decubitus position (Figure 1). Extra care

Drs Hakki and Oliveira are from Bay Pines Health Care System in Bay Pines, Florida.

Dr. Hakki is a consultant for B. Braun Aesculap. ORTHOPEDICS was unable to determine whether Mr. Dordelly and Dr. Oliveira have any relevant financial relationships to disclose or whether they are paid consultants for any companies.

Correspondence should be addressed to: Sam Hakki, MD, PO Box 22429, St. Petersburg, FL. 33742.

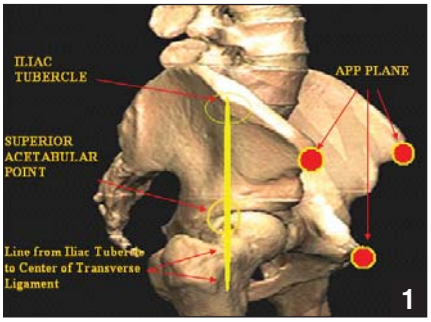

Figure 1: APP plane.

was taken to ensure the stability of the pelvis during registration by stabilizing the pelvis with three posts (pegs) positioned anterior to and three pegs positioned posterior to the pelvis (Figure 2). The ACA registration was done by three points of palpation of the superior rim, three points of the most anterior rim, and three points of the most posterior rim of the acetabulum. The superior point must be chosen carefully so that the pelvic tilt can be kept constant. We determined the superior point of the acetabulum by palpating the iliac tubercle. A line drawn from the iliac tubercle to the center of the transverse ligament will cross the superior rim of the acetabulum at the desired point of registration. The computer will average the points (Figure 3) and map out the anatomy and orientation of the acetabulum, which will determine the acetabular center axis (ACA). This axis will guide the surgeon as to where to position the reamer for placement at the center of the acetabulum. The surgeon will have the option of choosing the desired version or inclination angle to accommodate individual patient anatomy.

The ACA and APP points were defined and registered in 34 consecutive patients who underwent OrthoPilot (B. Braun Aesculap, Tuttlingen, Germany) navigated press-fit Excia (B. Braun Aesculap) THA. To avoid common pitfalls of APP registration, care was taken to ensure that the registration of the APP plane was as accurate as possible by carefully securing the positioning of the

Figure 2: Pelvis position secured.

patient and ensuring the equidistance between the registration point on the skin and the APP bony landmarks.

Preoperative plain pelvis radiographs with anteroposterior and cross-table lateral views were taken as routine. They were used to template the expected cup size in comparison with acetabular anatomy. Postoperative CT measurements of acetabular and cup inclination and version angles were observed independently using special software. Comparison of data was achieved using Fisher test and Student *t* test. The level of significance between CT and the variable should approach 1.0, which means the variable is as good as CT, when $P < .05$, the variable is significantly inferior to CT.

Results

Of the 36 consecutive patients, 34 were eligible for analysis of their hip data.

Mean anatomic (CT) acetabular version (ie, control) was 18.2º (SD ± 5.8), compared with 17.9º (SD ± 7.9) with ACA software. The mean anatomic (CT) acetabular inclination was 47.56º (SD ± 10.7). This reflects the validity and reliability of ACA software in identifying the version and inclination of the acetabulum.

Cup implant version (CT) was 22.97° (SD ± 9.4), compared with 23.0° (SD ± 8.4) for the ACA software and 12.7° (SD ± 12.1) for the APP software. This reflects reliably and

Figure 3: A, ACA superior. B, ACA anterior. C, ACA posterior.

statistical superiority of ACA software in identifying the version of the cup implant ($P = .98$), whereas the P value for the APP was significantly inferior to that for CT ($P = .0002$).

We then divided the patients into three groups according to anatomic variations of the acetabulum (normal, protrusio, and dysplastic). In the first group, the size of the cup closely matched the size of the acetabulum (normal acetabulum). The anatomic (CT) cup version was 21.7° (SD ± 10.3), compared with 21.7° (SD ± 8.8) for the ACA software ($P = 1.0$) and 11.37° (SD ± 10.5) for the APP soft-

ware (P = .003). ACA software produced results identical to CT; however, the APP software was significantly inferior to CT.

In the second group, the size of the cup implant was smaller than the acetabulum (as in protrusio hips or in acetabulum with large osteophytes). The anatomic cup (CT) version was 22.0° (SD ± 9.9), compared with 22.8° (SD ± 9.5) for the ACA software and 14.3° (SD ± 15.9) for the APP software. Interestingly, both ACA and APP software were not statistically different in the protrusio group (P = .89 and .38, respectively).

In the third group, the size of the cup was larger than the acetabulum (as in dysplastic hips or the cup implant was larger by choice). The anatomic (CT) version was 26.3° (SD ± 7.1), compared with 26.5° (SD ± 6.4) for ACA software and 14.9º (SD ± 14.3) for APP software. Again, ACA software was as accurate as CT (P = .96), whereas APP software was less accurate (P = .04). Finally, when we compared the accuracy of detecting the version of the cup implant between ACA and APP software, there was a statistical difference between the two (P = .0001).

As for the inclination angle of the cup implant, mean anatomic (CT) cup inclination angle for all groups was 43.5° (SD ± 4.2), compared with 43.5° (SD ± 7.5) for the ACA software and 41.1° (SD ± 4.7) for the APP software. Both ACA software (P = 1.0) and APP software (P = .44) were accurate in detecting the inclination angle of the cup.

Similarly, we divided the patients into three groups for cup inclination comparisons. In the first group, the cup matched the acetabulum, the anatomic cup inclination angle was 42.7° (SD ± 3.6), ACA inclination was 43.1° (SD ± 4.7) (P = .73), and APP inclination was 40.4° (SD ± 4.7) (P = .097). Again, both ACA software and APP software were accurate. In the second group, the cup size was smaller than the acetabulum (representing protrusio), the CT-scan inclination angle was 42.6° (SD ± 4.0), ACA inclination was 46.8° (SD ± 6.6), and APP inclination was 42.2° (SD ± 4.0). Both software were accurate (P = .92). In the third group (representing dysplastic), the cup size was larger than the acetabulum, the anatomic cup inclination angle was 46.0° (SD ± 4.8), ACA inclination was 42.7 (SD ± 12.2) (P = .45), and APP inclination was 42.0° (SD ± 5.5) (P = .12). There was no statistical difference between ACA and APP software in detecting inclination angle in all types of acetabulae (normal, protrusio, or dysplastic) (P = .11).

In conclusion, ACA software was statistically superior to APP software in detecting the version of the cup. There was no statistical difference in the accuracy of the inclination angles between APP and ACA software. Both methods were within safety zone of Lewinnek.

Discussion

The anterior pelvic plane has been the corner stone of image-based hip navigation technologies. Cup orientation is usually defined by referencing the anterior pelvic plane (APP).[4,7-9] However, the APP does not consistently represent the functional pelvic position, and a small error in correctly identifying this plane results in a significant error in cup placement. Consequently, cup position parameters are not patient specific.[10] Some centers recommended ultrasonography to identify APP with higher accuracy.[6] However, this has been done in the supine position and, unfortunately, the accuracy was diminished in the lateral decubitus position. Other centers recommend acquiring the APP coordinate system landmarks in the supine position before turning the patient to the side, but this can be impractical and increases operative time with possible compromise to sterility. We conducted this study with the patient in the lateral decubitus position despite the limitation of the APP registration process in accessing the opposite ASIS. We attempted to overcome this limitation by measuring the distance between the palpation points and the bony landmarks to be registered with a ruler. We made every effort to make such distance equal and to be secure by padding or adjusting the pelvic position. Also, the movement of the pelvis was minimized by placing three pegs anteriorly and three pegs posteriorly to secure the pelvis.

The reliability of the OrthoPilot navigation system has been tested,[6] and special software that independently reads both the APP and ACA registration points was developed and the data compared with postoperative CT of the pelvis as a control. Similar to the APP software, ACA software can accurately identify the cup orientation intraoperatively. However, ACA software supersedes APP software, which is easier to register and is independent of the pelvic position (movement during registration) and normal variations in anatomy. CT of the pelvis revealed significant variation of normal acetabulum version anatomy ranging from 5° to 30° of anteversion, where as the anatomic CT inclination angle range was less variable (47° ± 4°). This puts the safety zone of Lewinnek[11] in question. For example, a cup version of 29° is outside the safety zone of Lewinnek, but it is the normal acetabular version anatomy of a specific patient. For these variations, one study[12] demonstrated that there is perhaps no ideal position for the cup (45° inclination and 20° anteversion) that can be used for all patients. Because of the wide range of inclination and anteversion figures, half of cases in the study were outside the safety zone recommended by Lewinnek. This is another reason we believe ACA software to be superior to APP. ACA is more patient specific. The usefulness of the ACA concept to determine the orientation of the normal acetabulum has been well documented by Murray.[13]

Is there a limitation to the usefulness of the ACA software if there is a pathological variation of the acetabular

anatomy (protrusio, dysplastic, or large osteophytes)? Will placing the cup implant in the ACA of the acetabulum re-create the original deformity and thus misplace the cup implant? That problem was resolved before the study began by obtaining standard pelvis A/P and cross-table lateral views preoperatively. If the acetabulum is determined to be dysplastic or the desired cup is larger than the acetabulum, templating will give an approximate inclination angle of the acetabulum and the cup. In protrusio, the acetabular inclination angle (<40°) is expected to be smaller than cup inclination angle, whereas in dysplastic cases (more than 50°), the acetabular inclination angle is expected to be larger than cup inclination angle. The difference in degrees is calculated and used intraoperatively to adjust the computer-navigated ACA measurement to the desired angle.

The computer will read the final cup position in the "normal" acetabulum anatomy as zero degrees. This means the cup should match exactly the individual acetabular anatomy. If the acetabulum is protrusio, the computer readings of inclination should be in the +ve (positive) range, which means that the cup will be smaller than the acetabulum. If the acetabulum is dysplastic, the computer reading of the cup inclination should be in the –ve (negative) range, which means that the cup is larger than the acetabulum and that some of the rim of the cup is outside the acetabulum. This will enable the surgeon to make the proper adjustment in grossly abnormal acetabulum to achieve the ideal cup position specific to each patient. However, no such adjustments are needed to determine the cup version.

Finally, this study shows that there are two techniques (APP and ACA) for referencing in the lateral position. They are statistically different in terms of accuracy in determining the cup version compared with CT. As for the inclination angle, both APP and ACA were accurate. However, our new reference axis (ACA) has the advantage of being patient specific and independent of variations in anatomy or pelvic position. The system relies on readily accessible anatomical landmarks of the acetabulum, making it significantly attractive for surgeons who use CT-free planning and navigation.

References

1. Cunningham DJ. Pelvis. In: Cunningham DJ, ed. *Cunningham's Textbook of Anatomy*. London: Hodder & Stoughton; 1922:255-260.
2. Jaramaz B, DiGioia AM, Blackwell M, Nikou C. Computer assisted measurement of cup placement in total hip replacement. *Clin Orthop Rel Res*. 1998; (354):70-81.
3. Zheng G, Marx A, Langlotz U, Widmer KH, Buttaro M, Nolte LP. A hybrid CT-free navigation system for total hip arthroplasty. *Comput Aided Surg*. 2002; 7(3):129-145.
4. Archbold HA, Mockford B, Molloy D, McConway J, Ogonda L, Beverland D. The transverse acetabular ligament: an aid to orientation of the acetabular component during primary total hip replacement. *J Bone Joint Surg Br*. 2006; 88(7):883-886.
5. Wolf A, Digioia AM, Mor AB, Zheng G, Jaramaz B. Cup alignment error model for total hip arthroplasty. *Clin Orthop Relat Res*. 2005; (437):132-137.
6. Kieffer H, Othman A. Ultrasound vs pointer palpation based method in THA navigation: a comparative study. *Orthopedics*. 2007; 30 (suppl 10):S153-S156.
7. Spencer JM, Day RE, Sloan KE, Beaver RJ. Computer navigation of the acetabular component: a cadaver reliability study. *J Bone Joint Surg Br*. 2006; 88(7):972-975.
8. Ohashi H, Matsuura M, Okamoto Y, Ebara T, Kakeda K, Takahashi S. Status of navigated total hip arthroplasty in dysplastic osteoarthritis. *Orthopedics*. 2007; 30 (suppl 10):S117-120.
9. Tannast M, Langlotz U, Siebenrock KA, Wiese M, Bernsmann K, Langlotz F. Anatomic referencing of cup orientation in total hip arthroplasty. *Clin Orthop Relat Res*. 2005; (436):144-150.
10. Pinoit Y, May O, Girard J, Laffargue P, Ala Eddine T, Migaud H. Low accuracy of anterior pelvic plane to guide the position of the cup with imageless computer assistance: variation of position in 106 patients. *Rev Chir Orthop Reparatrice Appar Mot*. 2007; 93(5):455-460.
11. Lewinnek GE, Lewis JL, Tarr R, et al. Incidence of dislocation following hiparthroplasty for patients in rehabilitation setting. *J Bone Joint Surg Am*. 1978; 60(2):217-220.
12. Laffargue P, Pinoit Y, Tabutin J, Giraud F, Puget J, Migaud H. Computer-assisted positioning of the acetabular cup for total hip arthroplasty based on joint kinematics without prior imaging: preliminary results with computed tomographic assessment. *Rev Chir Orthop Reparatrice Appar Mot*. 2006; 92(4):316-325.
13. Murray DW. The definition and measurement of acetabular orientation. *J Bone Joint Surg Br*. 1993; 75(2):228-232.

Comparison Between Pointer-based and Ultrasound-based Navigation Technique in THA Using a Minimally Invasive Approach

Olaf Hasart, MD; Carsten Perka, MD; Stephan Tohtz, MD

abstract

The use of navigation techniques in primary total hip arthroplasty improves the position of endoprosthetic components, especially cup positioning. An intraoperative registration of the anterior pelvic plane is necessary to define the anteversion and inclination angles on the acetabular side. This study compares the accuracy of manual pointer palpation to ultrasound registration in navigation to determine pelvic plane registration in 60 cases of minimally invasive surgical technique. Findings show more accurate postoperative radiographic anteversion with ultrasound navigation, although both manual pointer palpation and ultrasound registration techniques show a very small standard deviation in anteversion, inclination, and leg length difference. In conclusion, we recommend navigation as a very reliable tool for the positioning of implants.

Arthroplasty of the hip joint is one of the most successful surgical measures in orthopedics. Preconditions for these good results are high-quality implants and soft tissue management, which enable precise implant positioning.

Long-term results of modern hip prosthesis are excellent, with approximately 95% survival rate after 10 years.[1-4] Since the definition of the so-called "safe zone" of Lewinnek was established, the planned final implant positioning can be determined.[5] Especially in terms of minimal invasive operative techniques with smaller skin incisions, soft tissue preserving approaches, and a decreased field of view, the incidence of malpositioning and the failure rate in endoprosthetic replacement are increasing.[6] The navigation ensures improved implant positioning[7,8] and therefore could compensate for the disadvantage of reduced visibility of landmarks associated with minimally invasive techniques. Ultrasound-based navigation is particularly advantageous,[9] because pelvic landmarks can be registered more easily than with pointer-based hip navigation.

The goal of this study was to compare ultrasound-based vs pointer-based navigation in minimally invasive primary hip replacement.

Material and Methods

Sixty patients were evaluated in this study. All patients were implanted with the same navigated cementless hip endoprosthesis (Plasmacup with polyethylene-inlay, ceramic head, and Excia stem; B. Braun Aesculap AG, Tuttlingen, Germany) using minimally invasive operating technique (anterolateral approach in supine position). Furthermore, the same surgeon performed the procedure in all patients. The navigation system used in all cases was the OrthoPilot with the software THAplus (B. Braun Aesculap AG).

Hip navigation was pointer based for group A and ultrasound based for group B (control group).

Pointer-based stem navigation was used in all patients (Figures 1, 2).

According to Lewinnek,[5] the aim for cup inclination was 40° to 45°. In case of cup anteversion, the antetorsion of the stem is important. Because of our preference for torsion position of the femoral components of 0°, the aim was a cup anteversion of 20° to 30°. The sum of both components (anteversion of cup plus

Drs. Hasart, Perka and Tohtz are from the Orthopaedic Department, Charité, in Berlin, Germany.

Drs. Hasart, Perka, and Tohtz are speakers for B. Braun Aesculap.

Correspondence should be addressed to: Olaf Hasart, MD, Orthopaedic Department, Charité, Charitéplatz 1, 10117 Berlin, Germany.

Figure 1: Intraoperative picture of pointer-based pelvic navigation; the reference point at the iliac crest is identical in both methods.

Figure 2: Intraoperative picture of ultrasound-based pelvic navigation, showing the uncovered iliac crests at both sides and the symphysis.

antetorsion of stem) should equal 20° to 30°.[10] Regarding leg length, balance with the opposite leg was attempted in all cases. Considering the absolute measured value of the displayed radiographs, a slight lengthening of the operated leg often occurs in comparison to the preoperative arthritic condition. Therefore, the comparison of leg length pre- and postoperatively as well as the comparison to the opposite leg was evaluated.

Evaluation of the implant positions in each case was based on standardized radiograph examinations (hip overview and lateral hip recordings) performed preoperatively and 2 weeks postoperatively.

The following is a comparison of radiograph results with data saved from the OrthoPilot.

The basis for this investigation was the acceptance of all patients. Only patients who provided written authorization for the use of their health records were enrolled in the study.

The aim of these investigations was the evaluation of the cup position (inclination and anteversion) as well as the determination of the leg length. In addition, the investigation sought to record intraoperative and postoperative complications.

Table 1

Patient Data in the Study Groups

	Pointer Based (n = 30)	Ultrasound Based (n = 30)	Significance
Age	68.4	69.1	NA
Sex			
Men	10	9	NA
Women	10	21	NA
BMI	27.3	28.2	NA
ASA	2.3	2.6	NA

Abbreviations: BMI, Body mass index; ASA, American Society of Anesthesiologists.

Results

Both groups were similarly matched for age, sex, body mass index (BMI), and criteria of American Society of Anesthesiologists (ASA) (Table 1). In the ultrasound-based group (group 2), the operation lasted slightly longer (5.2 min; $P < .05$). Intraoperative blood loss was equivalent between both groups (362 vs 375 mL; $P = .08$).

Evaluation of the cup position showed no difference for mean value in inclination and anterversion. The comparison of deviation showed a slightly smaller deviation in anteversion in group B (Table 2). There was no difference in deviation with regard to cup inclination.

Evaluation of leg length discrepancy showed no difference between the groups (Table 3). There were no differences in complications between the two groups. There was no hip dislocation or implant dislocation in either group.

Discussion

An important result of this study is that we could evaluate whether navigation enables precise cup positioning and implantation depth of the stem. The deviation of the implant positioning is considerably smaller than that reported in studies without navigation. Even experienced surgeons noticed deviations

of the cup inclination of 26° to 64°.[8] Cup anteversion seems to present a sharper distinction. In these cases, deviations of 9° to 53° were reported.[8] These indications are confirmed in the meta-analysis of Gandhi et al.[7] In the evaluation of the navigated cup positioning, this group discovered outliers of 10.7% from the interval recommended by Lewinnek[5] in comparison with 41.8% outliers in non-navigated cup positioning. This difference was highly significant ($P < .001$). Medium- to long-term malpositioning of the cup results in greater wear and cup loosening.[11] Therefore, the longevity and long-term result of a hip prosthesis significantly depend on the cup position. In this study, we could demonstrate that the ultrasound-based navigation enables minimization of the deviation of the anteversion of the cup. The reason for this seems to be the more precise display of the osseous landmarks, which depends less on the soft tissue over them than that in the case of pointer-based navigation. This result is an advantage of ultrasound-based navigation. A slightly longer operating time has to be taken into consideration. Furthermore, the operating cover has to be modified (the contralateral iliac crest stays uncovered). This procedure requires extra time.

The position of the stem influences significantly both the complication rate as well as the long-term result. In this study, we found only a maximum 2-mm lengthening on the unilateral side in all navigated hip replacements compared with the contralateral leg. The advantage of stem navigation is intraoperative measurement of leg length, which seems to be very helpful and reasonable.[12] Only small differences, such as 5° abduction or adduction of the leg, can affect leg length difference up to 8 mm,[13] so a misinterpretation may occur in clinical testing. Additionally, a higher range of malpositioning or malrotation can result without the use of navigation, and the rate of loosening and shorter survival rate of implants should be discussed in this context.[14]

We found that navigation of the cup and stem is helpful to achieve the best implant position. However, surgeons must define the correct position further.

Table 2

Results of Cup Positioning in Degrees

		Pointer Based (n = 30)	Ultrasound Based (n = 30)	Significance
Inclination				
	Mean	43.2	42.6	NA
	Range	38.1-47.0	37.0-46.8	NA
Anteversion				
	Mean	25.0	23.9	NA
	Range	13.8-30.5	16.1-27.8	$P < .05$

Table 3

Results of Stem Position in Dependence on the Measuring Method

	Pointer based (n = 30)	Ultrasound based (n = 30)	Significance
Comparison of leg length to:			
Preoperative	4	3	NA
Contralateral	2	2	NA

Operated side preoperative to postoperative
Postoperative, comparison with the contralateral side; values are mean in millimeters.

CONCLUSION

Navigation is a secure and recommended system for optimizing implant positioning with no increase in complications. It offers an advantage in cases of smaller field of visibility of the operating situs as in minimally invasive approaches because the risk of malpositioning is higher. In minimally invasive approaches, we could demonstrate that both ultrasound-based and pointer-based hip navigation are approaches that produce lower rates of malpositioning as described.[15] Additionally, ultrasound-based navigation provides higher precision of positioning in anteversion of the cup. The navigation is recommended for primary hip replacement as additional support in implant positioning.

REFERENCES

1. Aldinger PR, Thomsen M, Mau H, Ewerbeck V, Breusch SJ. Cementless Spotorno tapered titanium stems: excellent 10-15-year survival in 141 young patients. *Acta Orthop Scand*. 2003; 74(3):253-8.
2. Reigstad O, Siewers P, Røkkum M, Espehaug B. Excellent long-term survival of an uncemented press-fit stem and screw cup in young patients: follow-up of 75 hips for 15-18 years. *Acta Orthop*. 2008; 79(2):194-202.
3. Siebold R, Scheller G, Schreiner U, Jani L. Long-term results with the cement-free Spotorno CLS shaft. *Orthopade*. 2001; 30(5):317-22.
4. Swedish National Hip Arthroplasty Register; Johan Kärrholm, Göran Garellick, Peter Herberts. Annual Report 2006. http://www.jru.orthop.gu.se/

5. Lewinnek GE, Lewis JL, Tarr R, Compere CL, Zimmerman JR.Dislocations after total hip-replacement arthroplasties. *J Bone Joint Surg Am*. 1978; 60(2):217-220.
6. Laffosse JM, Chiron P, Molinier F, Bensafi H, Puget J. Prospective and comparative study of the anterolateral mini-invasive approach versus minimally invasive posterior approach for primary total hip replacement. Early results. *Int Orthop*. 2007; 31(5):597-603. Epub 2006 Oct 12.
7. Gandhi R, Marchie A, Farrokhyar F, Mahomed N.Computer navigation in total hip replacement: a meta-analysis. *Int Orthop*. 2008 Apr 3. [Epub ahead of print]
8. Haaker RG, Tiedjen K, Ottersbach A, Rubenthaler F, Stockheim M, Stiehl JB.Comparison of conventional versus computer-navigated acetabular component insertion. *J Arthroplasty*. 2007; 22(2):151-159.
9. Kiefer H, Othman A: Ultrasound vs pointer palpation based method in THA navigation: a comparative study. *Orthopedics*. 2007; 30(10 suppl):S153-S156.
10. Widmer KH, Zurfluh B. Compliant positioning of total hip components for optimal range of motion. *J Orthop Res*. 2004; 22(4):815-821.
11. Garcia-Rey E, Garcia-Cimbrelo E: Long-term results of uncemented acetabular cups with an ACS polyethylene liner: a 14-16-year follow-up study. *Int Orthop*. 2007; 31(2):205-210.
12. Ecker TM, Tannast M, Murphy SB: Computed tomography-based surgical navigation for hip arthroplasty. *Clin Orthop Relat Res*. 2007;(465):100-105.
13. Sarin VK, Pratt WR, Bradley GW. Accurate femur repositioning is critical during intraoperative total hip arthroplasty length and offset assessment. *J Arthroplasty*. 2005; 20(7):887-891.
14. Heller MO, Kassi JP, Perka C, Duda GN. Cementless stem fixation and primary stability under physiological-like loads in vitro. *Biomed Tech (Berl)*. 2005; 50(12):394-399.
15. Kalteis T, Handel M, Bäthis H, Perlick L, Tingart M, Grifka J: Imageless navigation for insertion of the acetabular component in total hip arthroplasty: is it as accurate as CT-based navigation? *J Bone Joint Surg Br*. 2006; 88(2):163-16s7.

Leg Length Discrepancy, Dislocation Rate, and Offset in Total Hip Replacement Using a Short Modular Stem: Navigation vs Conventional Free-hand

NORBERTO CONFALONIERI, MD; ALFONSO MANZOTTI, MD; FABRIZIO MONTIRONI, MD; CHRIS PULLEN, MD

abstract

We present a match-paired study between computer-assisted and free-hand techniques using a short modular femoral stem (Metha; B. Braun Aesculap, Tuttlingen, Germany) in total hip replacement (THR). Surgical time, clinical outcome, dislocation rate, limb length, and offset in 44 patients with ideal indication for this more conservative implant were assessed. Despite both longer surgical time and similar early outcomes, the results showed how computer-assisted techniques allow easier management of limb length discrepancy and offset restoring. We believe that navigated short modular stems are safe for less invasive THR.

Interest in minimally invasive total hip replacement (THR) has increased in the orthopedic community.[1,2] Most of the attention has been directed toward reducing surgical exposure by using dedicated instruments.[3] One driver of this change is the more frequent use of joint replacements in young active patients. In this group, preserving bone stock is more important because there is a potential increased need for revision procedure.[4] Recently, short femoral stems have become available for THR in these patients. These stems allow preservation of the femoral neck and have shown early positive results in selected cases.[5-7] Stem modularity and navigation technology to support correct implant selection and alignment are some of the newer innovations designed to optimize the accuracy of joint reconstruction using shorter femoral stems. Computer navigation allows the surgeon to evaluate limb length, medialization of the center of rotation, and ROM intraoperatively.[8,9]

Leg length discrepancy after THR can be a significant problem and has been shown to contribute to patient dissatisfaction.[10,11] Pain, instability, stiffness, neuropathy, and heterotopic ossification are all described as a direct or indirect consequence of leg length discrepancy and incorrect femoral offset.[12]

Reports indicate substantial statistical improvement in the accuracy of acetabular cup placement using navigation compared with free-hand alignment methods.[3,4] However, few studies have been published on the results of femoral stem placement using computer navigation and none evaluating the effect of navigation on leg length discrepancy.[13-16]

We performed a matched-paired study of two groups of modular short stems in hip arthroplasty with (computer-assisted THR) and without navigation support. We hypothesized that computer-assisted THR achieves a better joint reconstruction with effective control over the leg length discrepancy. Furthermore we compared the two groups according to hip function and number of postoperative dislocations.

MATERIALS AND METHODS

Patients who underwent THR using modular short-stemmed femoral components between April 2006 and January 2008 were included in the study. All patients had a body mass index less than 35. Patients with hip dysplasia, limb length discrepancy greater than 2 cm, or a major deformity of the femoral head or neck were excluded because they were not appropriate candidates for this implant.

Drs. Confalonieri, Manzotti, and Montironi are from the Ist Orthopaedic Department, Centro Traumatologico ed Ortopedico (C.T.O.) Hospital – I.C.P., Via Bignami 1, Milan, Italy.

Drs. Confalonieri, Manzotti, and Montironi report a congress sponsorship from B. Braun Aesculap. Dr. Pullen has no relevant financial relationship to disclose.

Correspondence should be addressed to Alfonso Manzotti, MD, Via S.Pertini 21, 20040 Cambiago, Milan, Italy.

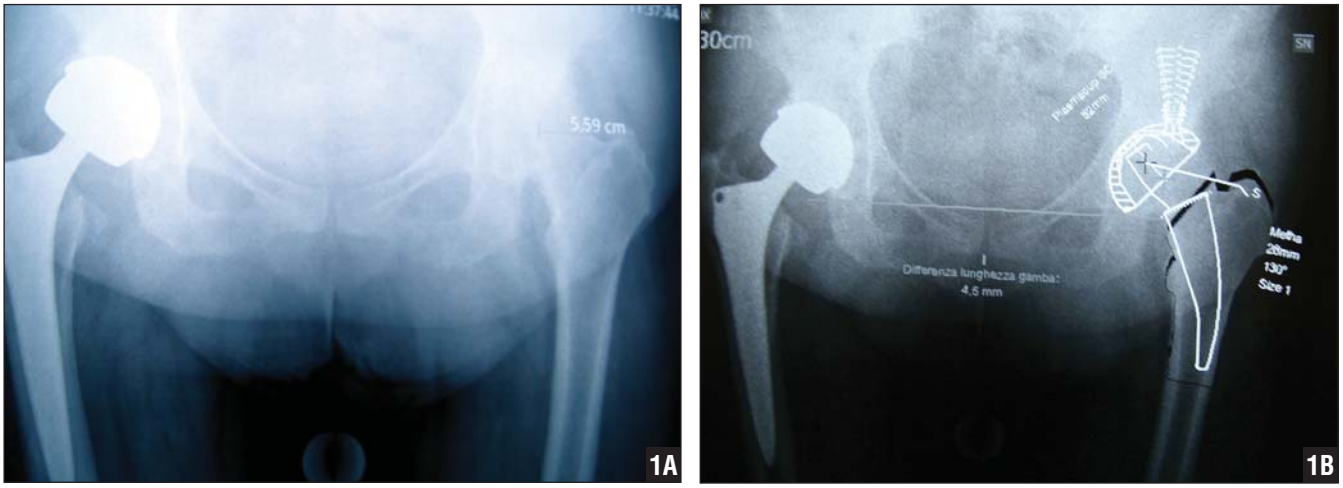

Figure 1: A, Preoperative pelvis radiograph of a 63-year-old woman previously operated on the right side with (B) relative preoperative planning.

Table 1

Demographic Data[a]

	Group A (Computer-assisted THR) (13 women)	Group B (THR) (13 women)
Age (y)	M, 60.4 SD, 5.2 R, 47-68	M, 60.8 SD, 4.8 R, 48-69
Follow-up (mo)	M, 10.8 SD, 6.08 R, 3-19	M, 11.6 SD, 6.08 R, 4-20
Preoperative discrepancy (mm)	M, 11.2 SD, 4.4 R, 0-20	M, 10.4 SD, 3.9 R, 3-19
Preoperative HHS	M, 43.95 SD, 3.31 R, 39-50	M, 43.4 SD, 2.98 R, 38-51
Preoperative diagnosis	18 hypertrophic osteoarthritis 3 avascular necroses 1 posttraumatic osteoarthritis	18 hypertrophic osteoarthritis 3 avascular necroses 1 posttraumatic osteoarthritis

Abbreviations: HHS, Harris Hip Score; THR, Total hip replacement.

a Patient demographic data for 22 cases are shown. Data are reported as mean value (M), standard deviation (SD), and range (R).

Twenty-two patients who underwent a computer-assisted THR using an imageless computed tomography-free, computer-assisted alignment system (OrthoPilot 3.0; B. Braun Aesculap, Tuttlingen, Germany) were included in group A. Each patient in this group was matched with a patient who had undergone conventional free-hand THR (group B). Patients were matched for age (maximum difference, +3 years), sex, arthritis level, preoperative diagnosis, and preoperative limb length discrepancy (maximum difference, + 0.3 cm). The length of involved limbs was less than or equal to that of the contralateral limb in all cases.

The same posterolateral approach was made to the hip joint in both groups, and the same prosthesis was used in all cases (Metha modular short stem and Plasma-Cup; B. Braun Aesculap). The duration of surgery was documented.

Preoperative and postoperative measurements of limb length discrepancy and femoral offset were made using digital radiographs as described by Woolson et al[17] with IMPAX digital radiography software (Agfa-Gevaert, Mortsel, Belgium) (Figure 1). At latest follow-up, the ability to re-create the femoral offset was determined by the difference between the pre- and postoperative femoral offset measures (Figure 2). All radiographs were taken with a standardized protocol using the same magnification. This protocol was rigidly adhered to during the study, and radiographs were repeated if a mistake was detected. All radiographs were assessed by an independent radiologist blinded to the original procedure.

Postoperatively, early weight bearing as tolerated was encouraged in all patients. All episodes of hip dislocation were documented. At a minimum follow-up of 3 months, the clinical outcome was evaluated using the Harris Hip Score.

Statistical analysis was carried out

Figure 2: Follow-up pelvis radiograph after the implantation of a navigated Metha stem (B.Braun Aesculap, Tuttlingen, Germany).

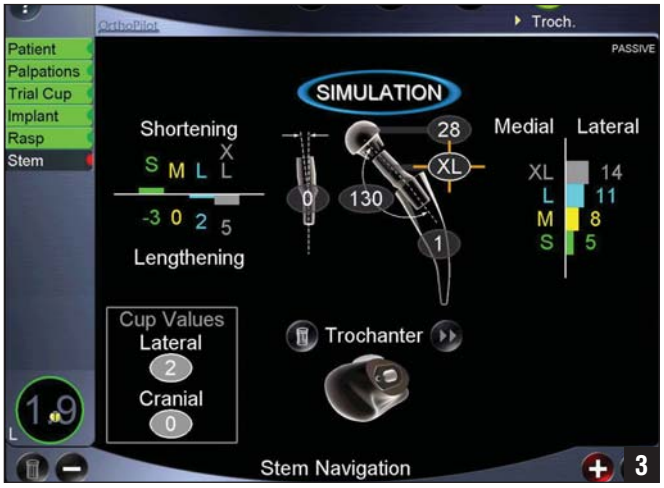

Figure 3: Screen shot showing the choices in modularity of the necks and different head sizes to manage the best joint reconstruction.

using SPSS for Windows Release 11.0 (SPSS Inc, Chicago, Illinois). Data were shown as a mean and SD for continuous response variables and as percentages for discrete variables. Differences between the two groups were measured with an independent Student's *t*-test or Mann-Whitney nonparametric test depending on the data distribution of the continuous variables.

RESULTS

No statistically significant differences in patient's demographics were seen. There were no significant differences in preoperative limb length discrepancy between the two groups. The mean preoperative leg length discrepancy was 0.9 cm in group A and 1.1 cm in group B (Table 1). In both groups, the preoperative diagnosis was primary hypertrophic osteoarthritis in 18 patients, avascular necrosis in 3 patients, and posttraumatic osteoarthritis in 1 patient (Table 1). The mean follow-up was 10.8 and 11.6 months for group A and B, respectively. The difference in length of follow-up was not statistically significant.

No intraoperative complications were encountered in either group. In group A, a 32-mm ceramic femoral head was used in 20 cases, whereas a 28-mm ceramic head was used in 2 cases. In group B, a 32-mm ceramic femoral head was used in 19 cases, whereas a 28-mm ceramic head was used in 3 cases. In the computer-assisted group, we noted marked variability in the femoral neck required in terms of inclination, version, and size to achieve anatomic best fit. Surgical time was statistically longer in group A, with a mean of 102.6 minutes compared with 87.7 minutes in group B (Table 2).

In the computer-assisted group, the mean postoperative leg length discrepancy was reduced to 0.4 cm compared with 0.8 cm in the free-hand group. This difference was statistically significant. No postoperative cases with leg length

Table 2

Postoperative Results[a]

	Group A (computer-assisted THR) (13 women)	Group B (THR) (13 women)	*P*
Surgical time (min)	102.5 min (R, 123-86) SD, 12.2	87.7 min (R, 68-105) SD, 11.7	.0001
Postop HHS	M, 90.1 SD, 6.0 R, 78-99	M, 89 SD, 6.5 R, 80-100	.5
Postop discrepancy (mm)	M, 4.1 SD, 1.7 R, 0-7	M, 7.9 SD, 2.8 R, 3-14	>.0001
Postoperative offset (difference in mm between the pre- and postoperative values)	M, 2.8 SD, 0.5 R, 0-6	M, 5.1 SD, 1.9 R, 2-9	.0002

Abbreviations: HHS, Harris Hip Score; THR, total hip replacement

a Postoperative results for the two groups. Data for 22 cases are shown. Data are reported as mean value (M), standard deviation (SD), and range (R).

discrepancy greater than 1.0 cm were seen in group A. In group B, a postoperative leg length discrepancy greater than 1.0 cm was seen in 2 patients (9%). No patient in either group had a postoperative leg length discrepancy over 2.0 cm, but 3 patients (13.6%) in group B had a postoperative overlengthening mean of 0.4 cm. At latest follow-up, no sign of major subsidence was seen in any of the implants.

Recreation of the femoral offset was significantly better in the computer-assisted group. The difference between the preoperative and postoperative femoral offset was less in the computer-assisted group than in the free-hand group (Table 2). This difference was statistically significant.

There were no statistically significant differences in the Harris Hip Score between the two groups, and all patients were satisfied with the outcome. The mean Harris Hip Score was 90.1 and 89 in groups A and B, respectively. For patients with a shorter follow-up, the final outcome was still improving (Table 2). No case of hip dislocation was seen in group A. In the group B, one patient experienced a traumatic hip dislocation following a car accident 7 months after surgery. This patient subsequently had two additional atraumatic dislocations but no radiographic signs of implant loosening. A revision THR is planned.

Discussion

Short-stem prostheses are an attractive alternative to resurfacing hip arthroplasty in the same selected indications.[4,6] Combined with minimally invasive techniques, these implants allow preservation of muscle and bone stock without introducing some of the complications associated with resurfacing implants.[18] With short-stemmed femoral implants, the femoral neck is partially maintained, and the greater trochanter region remains untouched. In addition, the femoral metaphysis is not filled by the implant, maintaining some of the cancellous bone.[4,6,8] Newer implants have incorporated modularity of the short femoral stem in an attempt to improve the restoration of hip anatomy and biomechanics and reduce the chances of mechanical failure (Figure 3).[8,9,19]

A significant problem with these short-stemmed femoral implants has been lengthening of the operated leg. In 2006, Lazovic showed that even with navigation support, this implant can lead to elongation of the leg by 1 to 1.5 cm.[9] This problem is also seen with resurfacing procedures and has led us to avoid using this technique in "longer hips."

Many studies have reported that improved placement of the acetabular cup and femoral stem can be achieved using navigation in THR.[13-16] Navigation of short-stemmed femoral implants is primarily based on the restoration of the hip anatomy with little regard for stem positioning.[8,9] The navigation can evaluate the best modular neck and head size intraoperatively to achieve the desired femoral offset, leg length, and range of motion. In this study, the computer-navigation support allowed for better exploitation of the different modular neck options to achieve the best anatomic fit.

We performed a matched-paired study comparing 22 computer-assisted and traditional free-hand THR procedures using the same modular short-stemmed femoral component. Strict criteria including diagnosis, age and sex, body mass index, and shortening were used to match the two groups. At a minimum follow-up of 3 months after surgical intervention, our results indicated that computer navigation produced statistically significant better results both in correcting limb length discrepancy and in restoring the original offset.

We acknowledge that our study had limitations. It was a retrospective analysis, and patients were not randomized. Follow-up was short, and the number of cases in each group was small. As a result, we may not have detected a clinical difference between the two groups, and findings regarding an improvement in the dislocation risk with this technique cannot be reported conclusively. However, no primary atraumatic dislocation was seen in patients from either group including those patients with longer follow-up.

Our results showed that using computer navigation in THR with modular short-stemmed femoral components can enhance the ability to correct limb length discrepancy and to restore the original femoral offset. We believe that given the correct indications, the navigated short-stemmed femoral prosthesis is a minimally invasive THR option that can restore normal joint biomechanics with results at least similar to those achieved with other more traditional techniques.

References

1. Sculco TP, Jordan LC. The mini-incision approach to total hip arthroplasty. *Instr Course Lect*. 2004; 53:141-147.
2. Dorr LD. The appeal of the mini-incision. *Orthopedics*. 2004; 27(9):937-938.
3. Kalteis T, Handel M, Herold T, Perlick L, Baethhis H, Grifka J. Greater accuracy in positioning of the acetabular cup by using an image-free navigation system. *Int Orthop*. 2005; 29(5):272-276.
4. DiGioia AM, Blendea S, Jaramaz B, Levison TJ. Less invasive THA using navigational tools. *Instr Course Lect*. 2004; 53:157-164.
5. Walker PS, Blunn GW, de Prada D, Casas C. Design rationale and dimensional consideration for femoral neck prosthesis. *Clin Orthop Relat Res*. 2005; 441:313-319.
6. Hube R, Zaage M, Hein W, Reichel H. Early functional results with the Mayo-hip, a short stem system with metaphyseal-intertrochanteric fixation [in German]. *Orthopade*. 2004; 33(11):1249-1258.
7. Gulow J, Scholz R, Freiherr von Salis-Soglio G. Short-stemmed endoprostheses in total hip arthroplasty. *Orthopade*. 2007; 36(4):353-359.
8. Röhrl SM, Li MG, Pedersen E, Ullmark G, Nivbrant B. Migration pattern of a short femoral neck preserving stem. *Clin Orthop Relat Res*. 2006; 448:73-78.

9. Braun A, Lazovic D, Zigan R. Modular short-stem prosthesis in total hip arthroplasty: implant positioning and the influence of navigation. *Orthopedics*. 2007; 30(10 suppl):S148-S152.

10. Lazovic D, Zigan R. Navigation of short-stem implants. *Orthopedics*. 2006; 29(10 suppl):S125-S129.

11. Konyes A, Bannister GC. The importance of leg length discrepancy after THA. *J Bone Joint Surg*. 2005; 87(B 9):155-157.

12. Clark CR, Huddleston HD, Schoch EP, Thomas BJ. Leg-length discrepancy after THA. *J Am Acad Orthop Surg.* 2006; 14(5):319.

13. Sarin VK, Pratt WR, Bradley GW. Accurate femur repositioning is critical during intraoperative THA length and offset assessment. *J Arthroplasty.* 2005; 20(7):887-891.

14. Nogler M, Kessler O, Prassl A, Donnely B, Streicher R, Sledge JB, Krismer M. Reduced variability of acetabular cup positioning with use of an imageless navigation system. *Clin Orthop Relat Res.* 2004; 426:159-163.

15. Kalteis T, Handel M, Bathis H, Perlick, Tingart M, Grifka J. Imageless navigation for insertion of the acetabular component in THA. *J Bone Joint Surg.* 2006; (88-B) 2:163-167.

16. Wixson RL, MacDonald MA. THA through a minimal posterior approach using imageless computer-assisted hip navigation. *J Arthroplasty*. 2005; 20(7 suppl3):51-56.

17. Lazovic D, Kaib N. Results with navigated bicontact total hip arthroplasty. *Orthopedics.* 2005; 28:S1227-S1233.

18. Woolson ST, Hartford JM, Sawyer A. Results of a method of leg-length equalization for patients undergoing primary total hip replacement. *J Arthroplasty*. 1999; 14(2):159-164.

19. Grupp T, Blömer W. Investigation of the loading stability of the modular conical connection [in German]. *Implant.* Aesculap AG & Co. KG. January 2005:6-8.

20. Berend ME, Bertrand T. Metal-metal hip resurfacing: solution to a nonexistent problem. *Orthopedics*. 2007; 30(9):724-727.

The Reliability of Navigation-guided Gap Technique in Total Knee Arthroplasty

SEUNG-BEOM HAN, MD; KYUNG-WOOK NHA, MD; JUNG-RO YOON, MD; DAE-HEE LEE, MD; IN-JUNG CHAE, MD

abstract

The OrthoPilot TKA navigation system (B. Braun Aesculap, Tuttlingen, Germany) offers software to optimize soft tissue balance using gap balance techniques. However, there are no studies on the reliability of the navigation-guided gap technique. The goal of this study is to establish the reliability of the navigation-guided gap technique. The investigators measured flexion and extension gap in the medial and lateral sides of the knee joint after bone resection to evaluate the reliability of navigation-guided soft tissue balancing. Gap data from 100 cases of navigation-guided total knee arthroplasty were analyzed. We defined trapezoidal gap (unsatisfactory soft tissue balance) as a gap difference > 3 mm between the medial and lateral sides in extension and a 5-mm difference in 90° of flexion. Furthermore, gap difference between flexion and extension greater than 3 mm on the medial side and 5 mm on the lateral side was also considered a trapezoidal gap. Among 100 cases, 84 showed rectangular (acceptable) gap, and 16 showed trapezoidal gap. We also evaluated the correlation between clinical results including range of motion and soft tissue balance as well as characteristics of trapezoidal gap. This study suggests that the navigation-guided gap technique is a reliable method for optimizing soft tissue balance.

Accurate limb alignment and well-controlled ligament balance after total knee arthroplasty (TKA) are critical to successful clinical outcomes and long-term prosthesis survival.[1,2] Malalignment and ligament imbalance could produce unequal load on the bearing surface and instability of the prosthetic joint, causing uneven wear of the polyethylene, early implant loosening, and poor clinical outcomes.[3] A close correlation between soft tissue balance and rotational alignment of the femoral component has been well understood.[4] In addition, soft tissue balance is influenced by whether a balanced flexion and extension gap is achieved intraoperatively.[5] However, soft tissue balancing remains a technically demanding and difficult part of TKA, because measuring the soft tissue tension is dependent on subjective surgeon assessment.[6] Therefore, measurements of the flexion and extension gaps are unreliable. The OrthoPilot TKA navigation system (B. Braun Aesculap, Tuttlingen, Germany) offers software that optimizes soft tissue balance, principally through the gap technique.

Over the past 10 years, many surgeons have become interested in computer navigation systems to perform more precise TKA. The initial results of navigation-assisted TKA are promising with regard to the restoration of mechanical limb alignment.[7,8] However, only a few studies have addressed the effectiveness and reliability of the navigation system on soft tissue balance in TKA. The purpose of this study is to determine the reliability of the navigation-guided gap technique and to evaluate the clinical results from adequate soft

Drs Han, Lee, and Chae are from the Department of Orthopedics, Korea University Medical Center, Seoul, Korea; Dr Nha is from the Department of Orthopaedic Surgery, Inje University, Ilsanpaik Hospital, Ilsan, Korea; and Dr Yoon is from the Department of Orthopedic Surgery, Seoul Veterans Hospital, Seoul, Korea.

Dr Han is a speaker on behalf of B. Braun Aesculap. Drs Nha and Chae have no relevant financial relationships to disclose. ORTHOPEDICS *was unable to determine whether Drs Yoon and Lee have any relevant financial relationships to disclose.*

Correspondence should be addressed to: Dae-Hee Lee, MD, Department of Orthopedics, Korea University Medical Center, Korea University College of Medicine, 126-1, 5-ga, Anam-dong, Seongbuk-gu, 136-705, Seoul, Korea.

tissue balance in TKA using the navigation-guided gap technique.

MATERIALS AND METHODS

TKA was performed on 108 osteoarthritic knee joints from 78 patients using the navigation-guided gap technique in our institution between May 2004 and June 2006. Eight patients were excluded from the study; two died from causes unrelated to TKA, two converted to conventional TKA owing to registration failure, and four were lost to follow up. Consequently, 100 knees from 70 patients were included in the study. Raw data, including gender, age at the time of surgery, preoperative range of motion (ROM), and duration of follow-up, were obtained from the prospective TKA database at our institution. The study group included 66 women, mean age was 67.1 years (range, 52-81 years), and mean follow-up was 2.3 years. The mean coronal plane alignment was 11.2° ± 5.1° in varus, preoperatively. All procedures were performed by the same surgeon (SBH). Study subjects underwent cruciate-retaining TKA with e.motion TKA system (B. Braun Aesculap). The patients who underwent posterior-stabilized TKA were excluded because posterior cruciate ligament resection might result in an unexpected increase of the flexion gap.[9,10] In all cases, the image-free navigation system (OrthoPilot version 4.0 or 4.2, B. Braun Aesculap) was used. All knees were accessed in a similar manner, using a midline skin incision with a medial parapatellar approach and routine soft tissue exposure. The preliminary ligament (usually medial) release, which is essential for the gap technique, was performed guided by real-time feedback from the navigation system.

A simple device similar to a lamina spreader with a torque meter and tensor with slide ruler was developed to measure the joint gap during surgery (Figure 1). After the preliminary release and tibial cutting, soft tissue tension was measured and registered to the navigation system with use of these devices. The OrthoPilot navigation system version 4.2 offers the femoral planning step that allows simulation of the femoral component sizing and rotation for the balanced gap (Figure 2). After completion of the bone cutting guided by the femoral planning step, the gap measurement was performed at the full extension and 90° of flexion in the medial and lateral side of the knee joint; medial extension gap, medial flexion gap, lateral extension gap, lateral flexion gap (shown in Figure 3). In this study, joint distraction force, which was applied between the osteotomized tibia and femur and was set at 40 lbs (18.7 kg), the joint gap with 40 lbs of distraction force at full extension most closely corresponds to the thickness of the insert actually selected for the procedure.[6]

We defined the trapezoidal gap (poorly balanced gap) as a gap difference greater than 3 mm between the medial and lateral sides in extension or 5 mm difference in 90° of flexion. Furthermore, difference between flexion and extension gap greater than

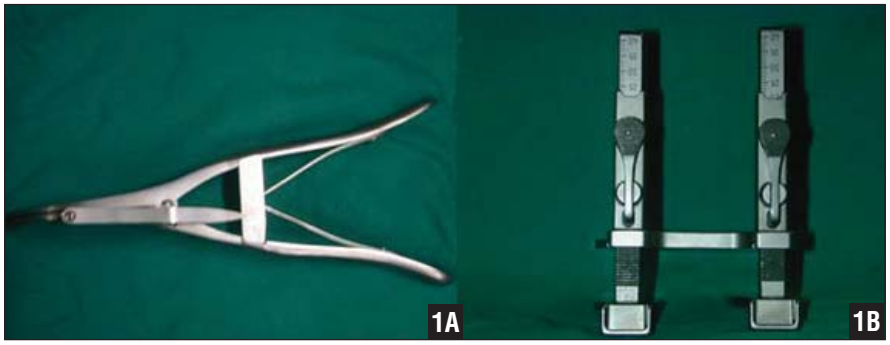

Figure 1: A simple device similar to a lamina spreader with a torque meter (A) and a tensor with slide ruler (B) was developed to measure joint gap.

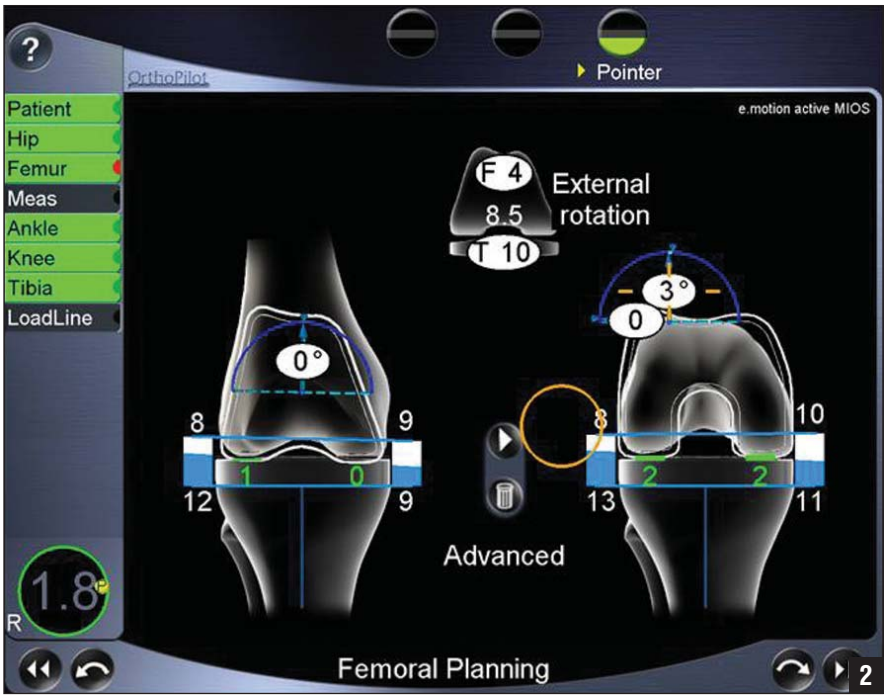

Figure 2: Femoral planning was performed to decide the size and rotation of the femoral component, which was a most useful step in OrthoPilot Navigation system.

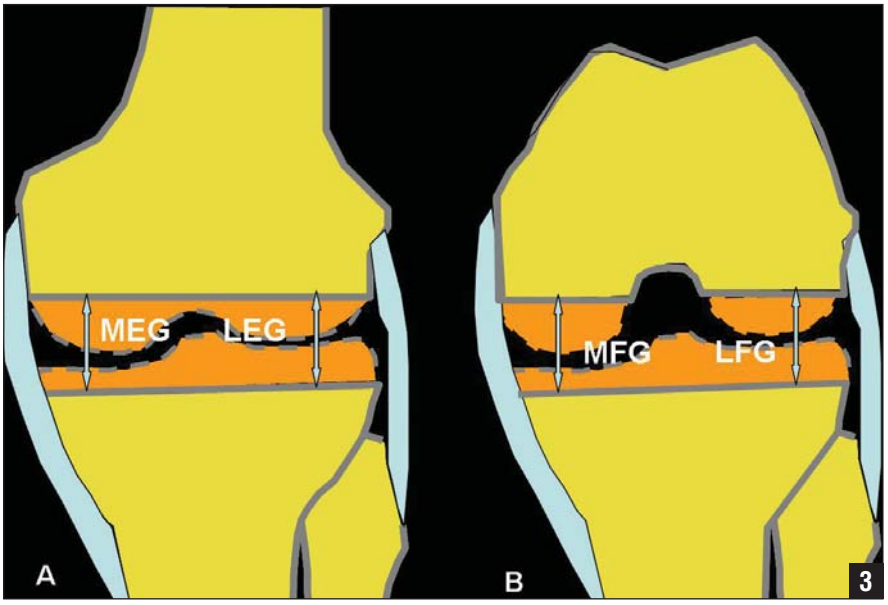

Figure 3: Gap measurements were composed of four folds. A, Medial and lateral extension gaps (MEG and LEG) and B, medial and lateral flexion gaps (MFG and LFG).

Table 1

Differences in Flexion, Extension, and Medial and Lateral Gaps[a]

mm

Gaps	0	1	2	3	4	5	>5
Flexion	36	36	19	7	1	0	1
Extension	31	43	14	10	1	0	1
Medial	31	31	17	12	8	3	3
Lateral	24	33	20	12	4	6	1

[a]*The difference between the medial and lateral measurements is reported for the flexion and extension gaps.*

3 mm in the medial side or 5 mm in the lateral side was also considered a trapezoidal gap (Figure 3B). Knees that did not meet the criteria for a trapezoidal gap were defined as having a rectangular gap (well-balanced gap). Based on our criteria for soft tissue balancing, patients were divided into two groups: a rectangular (well-balanced gap) group and a trapezoidal (poorly balanced gap) group. Moreover, gap difference in 90° of flexion (medial flexion gap~lateral flexion gap), extension (medial extension gap~lateral extension gap), medial (medial flexion gap~medial extension gap), and lateral (lateral flexion gap~lateral extension gap) side was analyzed to detect outliers and evaluate the reliability of gap balancing based on Griffin's method.[11]

Hospital for Special Surgery (HSS) scores and ROM at latest follow-up were used for the clinical outcome assessment. Mechanical alignment of the limb was checked on a standing radiograph of the entire lower extremity obtained at the latest follow-up. Mechanical axis measurements were performed by one of the investigators, who was blinded to the adequacy of balancing and clinical outcome.

Statistical analysis was performed using SPSS version 12.0 (SPSS Inc., Chicago, Illinois) for Windows. Clinical outcomes and radiological data in the two groups (rectangular and trapezoidal group) were analyzed using Fisher's exact test. Repeated measures ANOVA was used to compare the medial flexion gap, medial extension gap, lateral flexion gap, and lateral extension gaps. A P value < .05 was considered statistically significant.

Results

Gap Measurements

The mean intraoperative gaps were 21.8 ± 2.5 mm, 22.6 ± 2.3 mm, 21.3 ± .2 mm, and 22.0 ± 2.3 mm for medial flexion gap, lateral flexion gap, medial extension gap, and lateral extension gap, respectively. No statistically significant differences were found between the groups with regard to these four variables (P = .629, repeated measures ANOVA). According to our criteria, 84 knees were classified in the rectangular group, and the remaining 16 knees were classified in the trapezoidal group.

A summary of the gap differences in flexion, extension, and medial and lateral gaps is given in Table 1. Of the 100 knees, 72 knees had flexion gaps balanced (medial flexion gap~lateral flexion gap) within 1 mm. Nineteen knees had a side-to-side difference of 2 mm, 7 had a difference of 3 mm, and 2 had a difference greater than 3 mm. Seventy-four knees had extension gaps balanced (medial extension gap~lateral extension gap) within 1 mm. Of the remaining 26 knees, 14 had asymmetry of 2 mm, 10 had asymmetry of 3 mm, and 2 had asymmetry > 3 mm. With regard to medial gap differences (medial flexion gap~medial extension gap), 57 (57%) knees were balanced within 1 mm. Of the remaining knees, 17 had a mismatch of 2 mm, 12 had a mismatch of 3 mm, 8 had a mismatch of 4 mm, 3 had a mismatch of 5 mm, and 3 had a mismatch of > 5 mm. With respect to lateral gap differences (lateral flexion gap~lateral extension gap), 57 knees were balanced within 1 mm. Of the remaining

Table 2

Comparison of Preoperative Demographic Data and Knee Function Between the Two Groups

	Rectangular Group (Range)	Trapezoidal Group (Range)	*P* value
Mean age (y)	65.3 (53-81)	66.7 (53-72)	.653
Men:Women	6:78	1:15	.131
Mean BMI (kg/m2)	27.5 (19.7-31.2)	26.7 (20.7-33.1)	.818
Mechanical axis	167.8° ± 5.2°a	166.6° ± 8.3°	.687
Mean ROM	115.3° (75°-150°)	113.7° (70°-140°)	.693
HSS score	48.8 (24-64)	49.9 (20-68)	.367

Abbreviations: BMI, body mass index; HSS, Hospital for Special Surgery; ROM, range of motion. [a] *<180°: varus; 180° = neutral; >180°: valgus*

knees, 20 had a mismatch of 2 mm, 12 had a mismatch of 3 mm, 4 had a mismatch of 4 mm, 6 had a mismatch of 5 mm, and 1 had a mismatch of greater than 5 mm.

Comparison of Clinicoradiologic Results Between the Rectangular and Trapezoidal Gap Group

Demographic data, mean body mass index, coronal alignment, and knee function (including ROM and HSS score) were not significantly different preoperatively between the two groups (Table 2).

At the latest follow up, mean ROM was 123.1° (range, 80°-150°) in the rectangular group and 120.3° (range, 85°- 150°) in the trapezoidal group. There was no statistically significant difference between the two groups ($P = .528$). Neither improvement of ROM and HSS score nor correction of coronal alignment was found to be significantly different between the two groups (Table 3).

DISCUSSION

Recently, navigation-guided TKA has been widely used for enhanced precision. Studies[12,13] have addressed the reliability of navigation-guided TKA in terms of restoration of mechanical axis of the limb, but, to our knowledge, there have been only a few reports that address the effectiveness and reliability of the navigation-guided technique regarding the soft tissue balancing.

A well-balanced gap is important to successful TKA. In this study, rectangular flexion and extension gaps were brought within 1 mm in about 70% of cases (72% in flexion, 74% in extension). Only two cases showed gaps greater than 4 mm. A rectangular gap, according to our definition, was achieved in 84% of all knees, with trapezoidal gaps achieved in the remaining 16%. Even the knees in the trapezoidal group had a relatively small amount of asymmetry in soft tissue balance, and only five cases showed an asymmetry greater than 5 mm.

Although the gaps measured in this study lacked sufficient statistical significance, there was a tendency for the flexion gap to be larger than the extension gap and a tendency for the lateral gap to be greater than the medial gap when there was inequality. Regarding the tendency for a larger flexion gap than an extension gap, a possible explanation is that we intended the equal or larger gap in flexion than in extension on both the lateral and medial sides. Although the knee ROM after TKA was influenced by various factors such as the flexion contracture, body mass index, degree of deformity, and preoperative ROM,[14,15] we believed that postoperative knee flexion could be improved to a certain extent by increasing the flexion gap slightly.[16,17] The degree to which we increased the flexion gap did not result in flexion instability. There is a report that several millimeters of laxity in the flexion gap resulted in increased patient satisfaction after TKA.[18]

It is not surprising that, in this study, the lateral gap tended to be larger than the medial gap, because the lateral ligaments of the normal knee are almost always slacker than the medial ligaments.[19] Therefore, noted above, this trend toward a larger gap on the lateral side compared with the medial side was also shown from our intention in favor of the theories that the tibiofemoral flexion gap at 90° of flexion in the normal knee was not rectangular and that lateral joint laxity was significantly more than medial joint laxity in in vivo study using magnetic resonance imaging.[20]

In this study, there was no statistically significant difference in ROM, HSS score, improvement of ROM, or restoration of limb alignment after TKA between the rectangular and trapezoidal groups. This finding could be attributed to the fact that even the knees in trapezoidal group had a relatively small amount of asymmetry in soft tissue balance.

The primary limitations of our study were relatively small sample size and short follow-up period. It is possible that some of the differences between the two groups might have reached statistical significance had the sample size been larger and the follow-up period been longer. Regarding the navigation-guided gap balancing in TKA, to our

Table 3

Comparison of Postoperative Clinicoradiologic Outcomes Between the Two Groups

	Rectangular Group (Range)	Trapezoidal Group (Range)	*P* value
Mean ROM	123.1° (80°-150°)	120.3° (85°-150°)	.528
Improvement of ROM	10° (-10°-50°)	13.1° (-25°-45°)	.263
HSS Score	91.2 (64-100)	89.7 (60-98)	.348
Mechanical axis	180° ± 2.2°	180.7° ± 2.6°	.887

Abbreviations: ROM, range of motion; HSS, Hospital for Special Surgery

knowledge, there had been only two published reports in the English-language literature. Moreover, those two studies[21,22] evaluated the gap balancing indirectly by measuring opening angles on varus and valgus stress radiographs. In contrast to previous reports, this study directly quantified the soft tissue balance by the gap measurements.

In conclusion, soft tissue balancing using navigation-guided gap technique was a reliable method for achieving symmetrical flexion and extension gaps. With the relatively short follow-up period, no significant difference in clinicoradiologic outcomes was noted between the rectangular and the trapezoidal groups. However, because our results could not extrapolate long-term factors such as wear and loosing of components, the interpretation of these clinical findings should be considered with caution.

References

1. Dorr LD, Boiardo RA. Technical considerations in total knee arthroplasty. *Clin Orthop Relat Res*. 1986; (205):5-11.
2. Insall JN, Binazzi R, Soudry M, Mestriner LA. Total knee arthroplasty. *Clin Orthop Relat Res*. 1985; (192):13-22.
3. Viskontas DG, Skrinskas TV, Johnson JA, King GJ, Winemaker MJ, Chess DG. Computer-assisted gap equalization in total knee arthroplasty. *J Arthroplasty*. 2007; 22(3):334-342.
4. Fehring TK, Valadie AL. Knee instability after total knee arthroplasty. *Clinical orthopaedics and related research*. 1994; (299):157-162.
5. Incavo SJ, Coughlin KM, Beynnon BD. Femoral component sizing in total knee arthroplasty: size matched resection versus flexion space balancing. *J Arthroplasty*. 2004; 19(4):493-497.
6. Tanaka K, Muratsu H, Mizuno K, Kuroda R, Yoshiya S, Kurosaka M. Soft tissue balance measurement in anterior cruciate ligament-resected knee joint: cadaveric study as a model for cruciate-retaining total knee arthroplasty. *J Orthopaedic Sci*. 2007; 12(2):149-153.
7. Song EK, Seon JK, Yoon TR, Park SJ, Bae BH, Cho SG. Functional results of navigated minimally invasive and conventional total knee arthroplasty: a comparison in bilateral cases. 2006; 29(10 suppl):S145-S147.
8. Walde TA, Burgdorf D, Walde H-J. Process optimization in navigated total knee arthroplasty. *Orthopedics*. 2005; 28 (10 suppl):8.
9. Bottros J, Gad B, Krebs V, Barsoum WK. Gap balancing in total knee arthroplasty. *J Arthroplasty*. 2006; 21 (4 suppl 1):11-15.
10. Matsumoto T, Mizuno K, Muratsu H, et al. Influence of intra-operative joint gap on post-operative flexion angle in osteoarthritis patients undergoing posterior-stabilized total knee arthroplasty. *Knee Surgery Sports Traumatol Arthrosc*. 2007; 15(8):1013-1018.
11. Griffin FM, Insall JN, Scuderi GR. Accuracy of soft tissue balancing in total knee arthroplasty. *J Arthroplasty*. 2000;15(8):970-973.
12. Song EK, Seon JK, Yoon TR, Park SJ, Cho SG, Yim JH. Comparative study of stability after total knee arthroplasties between navigation system and conventional techniques. *J Arthroplasty*. 2007; 22(8):1107-1111.
13. Tingart M, Lüring C, Bäthis H, Beckmann J, Grifka J, Perlick L. Computer-assisted total knee arthroplasty versus the conventional technique: how precise is navigation in clinical routine? *Knee Surgery Sports Traumatology Arthrosc*. 2008;16(1):44-50.
14. Harvey IA, Barry K, Kirby SP, Johnson R, Elloy MA. Factors affecting the range of movement of total knee arthroplasty. *J Bone Joint Surg Br*. 1993; 75(6):950-955.
15. Ritter MA, Berend ME, Harty LD, Davis KE, Meding JB, Keating EM. Predicting range of motion after revision total knee arthroplasty: clustering and log-linear regression analyses. *J Arthroplasty*. 2004; 19(3):338-343.
16. Edwards E, Miller J, Chan KH. The effect of postoperative collateral ligament laxity in total knee arthroplasty. *Clin Orthop Relat Res*. 1988; (236):44-51.
17. Warren PJ, Olanlokun TK, Cobb AG, Walker PS, Iverson BF. Laxity and function in knee replacements. A comparative study of three prosthetic designs. *Clin Orthop Relat Res*. 1994; (305):200-208.
18. Kuster MS, Bitschnau B, Votruba T. Influence of collateral ligament laxity on patient satisfaction after total knee arthroplasty: a comparative bilateral study. *Arch Orthopaedic Trauma Surg*. 2004;124 (6):415-417.
19. Whiteside LA, Kasselt MR, Haynes DW. Varus-valgus and rotational stability in rotationally unconstrained total knee arthroplasty. *Clin Orthop Relat Res*. 1987; (219):147-157.
20. Tokuhara Y, Kadoya Y, Kanekasu K, Kondo M, Kobayashi A, Takaoka K. The flexion gap in normal knees. An MRI study. *J Bone Joint Surg Br*. 2004; 86(10):1133-1136.
21. Picard FF, Deakin AHAH, Clarke JVJV, Dillon JMJM, Gregori AA. Using navigation intraoperative measurements narrows range of outcomes in TKA. *Clin Orthop Relat Res*. 2007; (463):50-57.
22. Seon JK, Song EK, Yoon TR, Bae BH, Park SJ, Cho SG. In vivo stability of total knee arthroplasty using a navigation system. *Int Orthop*. 2007; 31(1):45-48.

One-year Follow-up of 214 Total Knee Arthroplasties With Navigated Columbus Implants

GOPI KATIPALLI, MRCS; ANGELA H. DEAKIN, PHD; JUSTINE GREAVES, BSC(HONS) SRP; TRACEY REYNOLDS, RGN; FREDERIC PICARD, MD

abstract

In this study, 206 patients with 214 Columbus total knee arthroplasty (TKA) implants were followed up at 1 year. Preoperatively, patient demographics (mean [SD]) were 85 male; age, 69.7 (8.7) years; ASA score, 2.5 (0.7); body mass index, 32.2 (5.7); 161° varus and 27° valgus; fixed flexion, 5.6° (6.1°); flexion, 96.1° (18.8°); and Oxford score, 43 (7.0). At 1-year follow-up, results were fixed flexion, 0.9° (2.6): maximum, 17°, minimum, 0°; flexion, 101.3° (9.1): maximum, 125°, minimum, 75°; and Oxford score, 23 (7.7). Radiographs showed radiolucent lines in 6 femurs in 1 zone; 1 in 2 zones and 0 in more than 2 zones; and 3 tibias in 1 zone. There were 2 deep infections. Ninety-eight percent of patients were satisfied with their TKA.

More than 65,000 total knee arthroplasty (TKA) operations are performed in England, Wales, and Scotland each year. Despite the overall success of this procedure, the outcome depends on several factors including patient selection, implant features, surgical technique, and postoperative follow-up. In 2003, the Agency for Healthcare Research and Quality (AHRQ) published a comprehensive report[2] that concluded that there was a lack of experimental methodology and longer-term results to categorically deduce TKA outcomes.[3] This series reviewed 214 computer-assisted TKAs, all carried out in a dedicated arthroplasty center, after 1 year. Notwithstanding a short-term result, we believe that we have an extremely strong experimental methodology. From preassessment through follow-up, this is a review of systematically collected data of all patients seen in the arthroplasty center. All patients received the same standard fixed-bearing knee design (Columbus; B. Braun Aesculap, Tuttlingen, Germany) implanted with the same image-free navigation system (OrthoPilot; B. Braun Aesculap) under similar anesthetic protocols. More importantly, the Arthroplasty Service at the center ensures high percentage, consistent quality follow-up that is independent from the surgeon. This has allowed us to assess the incidence of the many short-term problems associated with TKA (infection, deep vein thrombosis, anterior pain) with this particular implant and surgical set-up. This is the first study reporting 1-year review of a series of Columbus-navigated TKAs. We compared our results with current series with similar condylar implants.

Although knees have been navigated for over 10 years, navigation is not yet a routine practice. Concerns about technical difficulties and the potential increase in complications have been raised in some reports, with the investigators concluding that navigation was either a disruptive technique or too new to be used on a regular base.[24,25] We hypothesized that using a nonimage-based navigation system did not affect our practice, the number of complications, or outcomes.

MATERIALS AND METHODS

A prospective continuous series of 206 patients underwent 214 Columbus-navigated TKA from March 8, 2005, to December 17, 2006, after informed consent was obtained from all patients. This included all patients assessed as suitable for TKA. Of these TKAs, 93% were performed by one surgeon. Preassessment selection was

Drs Katipalli, Deakin, Greaves, Reynolds and Picard are from the Department of Orthopaedics, Golden Jubilee National Hospital, Clydebank, Glasgow United Kingdom.

Dr Picard has a patent license from B. Braun Aesculap. ORTHOPEDICS was unable to determine whether Drs Katipalli, Deakin, Greaves and Reynolds have any relevant financial relationships to disclose.

Correspondence should be addressed to: Frederic Picard, MD, Department of Orthopaedics, Golden Jubilee National Hospital, Clydebank, Glasgow, G81 4HX, United Kingdom.

Table 1

Demographics of Age, BMI, and Scores for Patient Cohort

	Mean	SD	Minimum	Maximum
Age	69.7	8.7	48	90
ASA	2.5	0.7		
BMI	32.2	5.7	21.8	51.5
Ahlback Score	3.9	0.6	3	5
Kellgren Lawrence Score	3.5	0.5	2	4

Abbreviations: ASA, American Society of Anesthesiologists; BMI, body mass index.

Table 2

Demographics of Gender, Side, and Etiology for Patient Cohort

Sex	85 males	121 females	
Side	93 right	105 left	8 bilateral
Etiology	OA = 188	RA = 4	Others = 14 (AVN, fracture, secondary OA)

Abbreviations: AVN, avascular necrosis; OA, osteoarthritis; RA, rheumatoid arthritis

rigorously performed by an arthroplasty team including physiotherapists, occupational therapists, arthroplasty nurses, senior hospital officers, anesthetists, and consulting surgeons. During the preassessment, extensive patient demographic data (Tables 1, 2) and medical history including preoperative function were collected. Preoperative radiographs including weight-bearing hip-knee-ankle, lateral, and skyline view were taken.

Of patients in this series, 60% were women. The average ASA score (2.5) indicated that most patients were very ill/fairly ill (ASA: 1 = 12; 2 = 92; 3 = 92; 4 = 10; total 206). The majority of patients (87%) had end-stage osteoarthritis, and there were more varus knees (83%). Seventy-nine percent had an Ahlback score (1-5) ⩾4, and 99% had a Kellgren-Lawrence score (1-4) ⩾3.

The usual anesthetic protocol included an epidural with 1.5 g of cefuroxime prior to skin incision. The patient was placed in the supine position, and the tourniquet was inflated at 300 mm Hg for the duration of the operation, when there were no neurovascular contraindications. The knee was flexed to approximately 90° and stabilized on the side with a lateral support and a sandbag underneath the foot. A midline skin incision was made, followed by either the medial parapatellar approach in most of the knees or by the lateral parapatellar approach in fixed valgus contracture knees.

The OrthoPilot navigation system was placed at the opposite side of the knee 2 m from the knee, and the LED active trackers were affixed solidly into the femur and the tibia. After registration that included kinematics and anatomic landmarks acquisition, the knee was assessed, initially in optimal extension and then in varus and valgus stress. The knee was then assessed from the maximum extension to the maximum flexion. Before making bony cuts, a release was performed according to the classification given by Unitt[26] and the measured preimplant varus/valgus stress results.[12] This gave a knee that was adequately balanced within ±3°. The flexion/extension angle was recorded and the tibial cut made. It was usual to cut 10 mm on the lateral side with respect to the normal joint line in varus knees and 8 mm in severe valgus knees. The normal joint level was recorded using the pointer. A plate probe equipped with a tracker allowed the checking of the actual bone cut resection and the measurement stored. The distal femoral cut was then performed using the computer-guided jig. Initially, 9 mm was cut from the distal femur, which was the distal thickness of our prosthesis. The plate probe was then placed flat against the actual cut and the reading stored. An additional 2-mm or occasionally a 4-mm distal femoral resection cut was made in case of non-correctable flexion contracture after adapted release. Rotation was usually set according to the Whiteside line but controlled with the computer.

The trial implants were set, and the assessment was performed under navigation. The leg was placed in full extension, and the varus/valgus stress measured. The range of motion of the knee from full extension to maximum flexion were assessed. Once satisfied with full assessment using the trial implants, the procedure was completed by cementing both femoral and tibial components using antibiotic-impregnated cement. Most implants were cruciate-retaining Columbus implants. A deep dish tibial insert rather than a standard inlay was sometimes used when the posterior cruciate ligament (PCL) seemed weak. Rarely, when there was still significant flexion contracture or a completely missing PCL, a posterior-stabilized implant was used. Seven patellar releases were performed, and none were resurfaced.

At the end of the procedure, with actual implants, the last assessment was recorded with knee in full extension, varus/valgus stress, and all the way from full extension to maximum flexion.

The wound was closed with either clips or sutures in three layers and then covered with a hydrocolloid dry dressing (DuoDerm; ConvaTec, Flintshire, United Kingdom) and a hydrogel inner layer (Aquacel,

Table 3

Comparison of Pre- and Postoperative Functional Measures

	Preoperative		Postoperative		Wilcoxon test
	Median	1st to 3rd Quartile	Median	1st to 3rd Quartile	*P* value
Oxford score	44	39.5 to 49	21.5	17 to 28	<.001[a]
Range of motion (°)	100	90 to 110	100	95 to 110	.025[b]
Fixed flexion (°)	5	0 to 10	0	0 to 0	<.001[a]

[a]: *n = 124.* [b]: *n = 123*

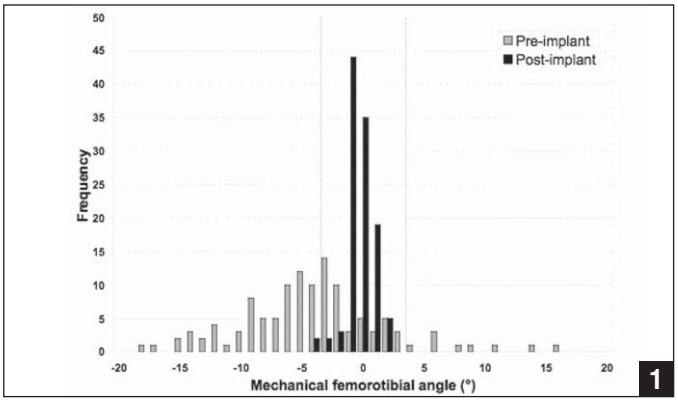

Figure 1: Distribution of pre- and postimplant coronal plane alignment angles as measured by the navigation system. Wilcoxon test *P* < .001 between groups (n = 110).

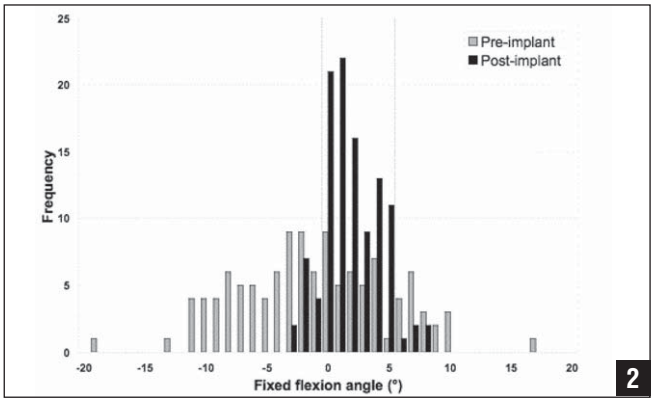

Figure 2: Distribution of pre- and postimplant sagittal plane alignment angles as measured by the navigation system. Wilcoxon test *P* < .001 between groups (n = 108).

ConvaTec) without any drainage. Patients were mobilized on the day of surgery or the day after, under a physiotherapist's supervision, using a Zimmer frame and then crushes or walking sticks. The postoperative protocol was standardized including early mobilization with full weight bearing and rapid range of motion (ROM) recovery. For thromboprophylaxis, the majority of patients received impulse boots, stockings, and aspirin 150 mg for 6 weeks but some had additional chemical thromboprophylaxis. Patients were discharged when occupational therapists and physiotherapists considered them autonomous and safe to return home. Outpatient physiotherapy was prescribed if needed, mainly in cases of unsatisfactory ROM. The dressing was changed before discharge and at the patient health center. Infection control nurses and arthroplasty nurses called the patients within the first 15 days to monitor progress. The wound was also assessed at the arthroplasty follow-up at 6 weeks.

Extended scope practitioners, who have undergone extensive training, staff our Arthroplasty Service. They organize follow-up for all patients at 6 weeks and 1 year. The follow-up assessment was carried out by independent practitioners who asked patients to complete an Oxford score questionnaire to assess ROM, the wound, general progress, and satisfaction and to identify any postoperative complications. Patients were referred to consultants for review only if a problem occurred. All data were then recorded in our proprietary electronic audit system, which is accessible only to the arthroplasty practitioners. An independent consultant reviewed radiographs randomly and measured the coronal mechanical femoral axis, sagittal mechanical femoral axis, coronal mechanical tibial axis, sagittal mechanical tibial axis, coronal femorotibial angles, and radiolucencies.

Statistical analysis was carried out using SPSS version 15.0 (SPSS Inc, Chicago, Illinois). Pre- and post operative data were compared using a Wilcoxon test.

Results

Of 206 patients, 203 were reviewed (211 knees). Two patients were lost to follow-up and 1 patient died during the year from causes unrelated to the knee surgery. After 1 year, 98% of the patients were very satisfied or satisfied. Of the 4 patients who remained unsure or unsatisfied, 1 was diagnosed with Alzheimer's disease and needed a difficult two-stage revision prosthesis for deep infection; one had a 17° flexion contracture; one with anterior pain underwent computed-tomography (CT) investigation; and one experienced problems

Table 4

Postoperative Complications

Complication	No.	%
Death	1	0.4
Infection	2	0.9
Pulmonary Embolism	1	0.4
Anterior Knee Pain	2	0.9
Complex Regional Pain	1	0.4
Tibial Tracker Site Superficial Skin Infection	1	0.4

with the other knee (loose unicompartmental knee that has since been revised).

No correlation was found between age, gender, BMI, degenerative stages, and satisfaction outcome.

The pre- and postoperative (1 year) Oxford scores, ROM, and fixed flexion from the clinic (Table 3) and the pre- and post-implant mechanical femorotibial angle and fixed flexion from the navigation system (Figures 1, 2) were compared. Wilcoxon test $P < .001$ between groups (n = 108).

Few complications occurred (Table 4 and listed below). Two severe deep infections required revision.

Average postoperative Haemoglobin was 11.1g/dL (1.5) and 6 of our patients received blood transfusions.

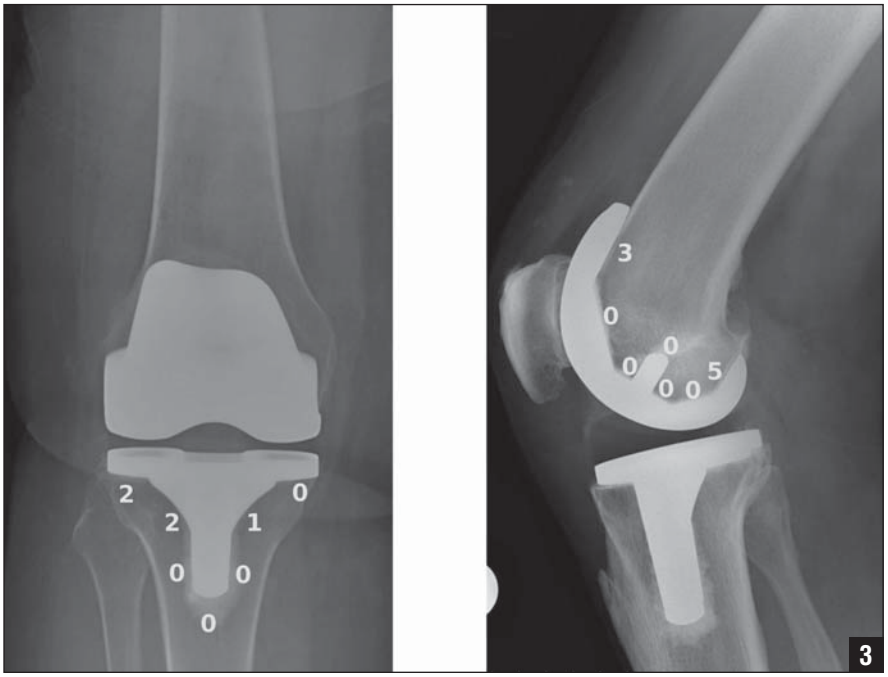

Figure 3: Radiolucencies measured on the postoperative radiographs for femoral and tibial components. Yellow numbers show counts of radiographs with radio-lucencies in that zone.

Discussion

This is a 1-year review of a prospective continuous study of 214 Columbus-navigated TKAs. Two patients were lost to follow-up, and one patient died of causes unrelated to the knee surgery. When asked at follow-up, 98% of patients were either satisfied or very satisfied. Among the four unsure or unsatisfied patients, three were functionally unsatisfied. It is known that the functional score continues to constantly improve after a TKA up to 2 years even though the literature cannot support specific recommendation about which patients are most likely to benefit from TKA and what type of implant or implant fixation method is most beneficial.[3] Our series showed statistically improved Oxford scores, confirming results from previous studies.[1,4] This study also confirmed that age, sex, BMI, and degenerative stage cannot predict a satisfactory outcome.[3]

Postoperatively, nine patients (4.2%) had an intermediate flexion contracture of between 6° and 19° according to Ritter's criteria.[6] In his review of 5622 TKAs, Ritter[6] found a preoperative flexion contracture rate of 26.5%. According to McPherson[5], flexion contracture after 1 year can continue to improve. McPherson[5] showed positive outcomes of more than 10º up to 3 years after surgery. This means that even the most severe cases (17°) can improve. Average flexion was 101.3° postoperatively, with ROM significantly improved. These figures are similar to those published by Walker, who reported average ranges of flexion angle from 100° to 110° after condylar knee surgery.[7] Some of the disappointing flexion angles were related to incomplete removal of posterior osteophytes (Figure 3) or limited preoperative flexion.

The primary postoperative development after TKA is femoropatellar complication, which ranges from 1.5% to 12% in incidence according to Lombardi.[8] In this series, two patients reported anterior pain (<1%), one underwent a secondary patellar resurfacing, and one underwent CT investigation to assess femoral and tibia rotation. The use of computer navigation may explain this low rate of anterior pain. In 2004, Stockl[9] and Chauhan[10] showed that computer navigation improved the femoral rotation position, and in 2006, in an experimental setting comparing various femoral rotation landmarks, Siston[16] showed that even when using navigation, inconsistent femoral rotation can occur. However, he also showed that Whiteside's line still could be a reliable reference especially with use of computer guidance. We demonstrated a similar outcome in 2007.[12] Computer navigation may improve alignment and may also decrease morbidity and complications such as operative bleeding.[21] Only 2.4% of our

patients underwent transfusion, which is less than that reported in recent series such Sundaram's,[20] claiming 8% transfusion in a group of 200 patients.

In a study by Callahan,[1] the mortality rate was 1.5% and the revision rate was 3.8%. In our series, two implants were revised for deep infection, one for patella resurfacing, and none for loosening, resulting in a 1.4% revision rate. In a 2008 article by Katz et al[13], that compared high to low TKA volume hospitals, he confirmed his previous conclusions[12] that high volume and special units are associated with fewer complications. Katz performs more than 200 TKR procedures yearly, which corroborates the following results (our results are shown in parentheses). The complication rate for mortality after TKA was between 0.53% and 0.62%.[14,15] After 1 year, one patient died from causes unrelated to surgery (0.4%). The pulmonary embolus rate was between 0.41% and 0.77%.[13,15] One patient experienced a nonfatal pulmonary embolism (0.4%). Deep infection rates are usually between 1% and 2%.[27] Two patients (<1% of the series) had a deep infection and underwent two-stage revision (both had BMI >35 and Charlson comorbidity index >2, which significantly increased the risk of infection). Infection remains the most challenging risk factor in TKA. Our patients are reviewed by their general practitioners within the first 2 weeks of surgery. Seven patients had antibiotics started by their GPs because of red wounds and other infections (chest, urinary tract infection). All these patients were followed clinically and had blood test at 6 weeks that ruled out TKA infections. In our series, the overall complication rate was 4% (compared with 18.1% in the Callahan review and 5.4% in the most recent review.[2,3] The main drawback of the navigation was operating time. The average operating time was 80 minutes, which is similar to the published results for navigated TKR.[11] Navigation slightly increases the standard operating time by 10 to 20 minutes because of the tracking setting and registration.

Table 5

Postoperative Radiograph Alignment in Coronal and Sagittal Planes

	Mean	SD	Minimum	Maximum
Coronal mechanical femoral axis	90.4	2	85	97
Sagittal mechanical femoral axis	86.4	4.3	76	96
Coronal mechanical tibial axis	88.1	2.4	83	94
Sagittal mechanical tibial axis	88.2	1.8	84	94
Coronal femoro tibial angle	179	2.3	173	186

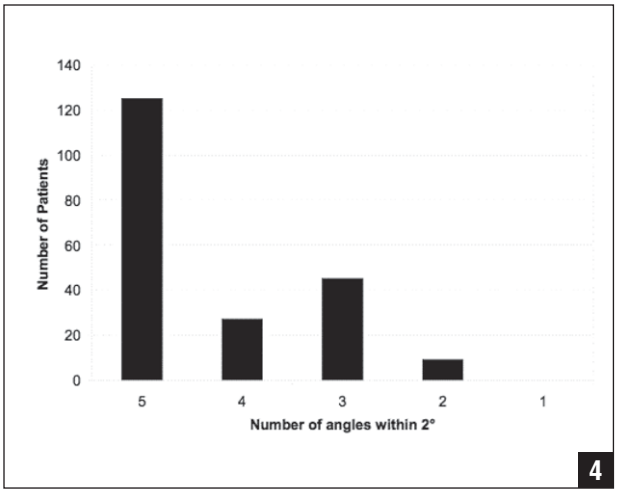

Figure 4: Grouping of alignment angles measured within 2° on postoperative radiograph for measurement of the coronal mechanical femoral axis, sagittal mechanical femoral axis, coronal mechanical tibial axis, sagittal mechanical tibial axis, and coronal femoro tibial angle showing how many patients had good alignment in all planes (n = 206).

The main advantage was to reproducibly align the TKAs. Postimplant measurements taken at the end of the surgical procedure using computer measurements showed excellent alignment in both the sagittal plane (1.4° ± 2.2°) and the coronal plane (0.1° ± 1.4°). These results were confirmed at the 6-week, long leg film review (Table 5). Using Jenny's criteria[22] to quantify the alignment reproducibility, we found that 71% of our implants had four component angles within 2° (including femur and tibia coronal and sagittal angles) (Figure 4). Another series of 306 TKA procedures done by one experienced surgeon using standard instrumentation showed only 52% alignment reproducibility.[19] These results confirmed the current meta-analyses from Bauwens[17] and Mason[18] demonstrating the potential benefit of navigation in alignment. Only long-term follow-up will indicate whether improving alignment increases implant survivorship. However, despite the short-term review, we found a few radiolucent lines less than 1 mm, with no loosening, which corroborate leg alignment improvement.[23] Most of these lines were not on the tibia but on the posterior femur, which was attributable to insufficient posterior cement (Figure 3).

The overall results of this extensive 1-year review of 214 TKAs are encouraging. These patients will be reviewed at 2, 5, and 10 years in our arthroplasty department, and we will report on long-term Columbus-navigated TKAs and verify whether navigation im-

proved implant survival. We confirmed that using a nonimage-based navigation system routinely does not affect our practice, the number of complications, or our outcomes.

REFERENCES:

1. Callahan CM, Drake BG, Heck DA, et al. Patient outcomes following tricompartmental total knee replacement. A meta-analysis: Postoperative alignment of total knee replacement. Its effect on survival. *JAMA*. 1994;271(17):1349-1357.
2. Kane RL, Saleh KJ, Wilt TJ, et al. Total Knee Replacement. *Evid Rep Technol Assess (Summ).* 2003;(86):1-8.
3. Saleh KJ, Mulhall KJ, Hofmann AA, et al. Primary Total Knee Arthroplasty Outcomes. In: Barrack RL, Booth RE, Lonner JH, eds. Orthopaedic Knowledge Update: Hip and Knee Reconstruction 3. AAOS; 2006:93-110.
4. Lizaur AL, Marco L, Cebrian R. Preoperative factors influencing the range of movement after total knee arthroplasty for severe osteoarthritis. *J Bone Joint Surg Br*. 1997; 79(4):626-629.
5. McPherson EJ, Cushner FD, Schiff CF, et al. Natural history of uncorrected flexion contractures following total knee arthroplasty. *J Arthroplasty*. 1994; 9(5):499-502.
6. Ritter MA, Lutgring JD, Davis KE, et al. The role of flexion contracture on outcomes in primary total knee arthroplasty. *J Arthroplasty*. 2007; 22(8):1092-1096.
7. Walker PS. Total knee implant design. In: Barrack RL, Booth RE, Lonner JH, eds. Orthopaedic Knowledge Update: Hip and Knee Reconstruction 3. AOS Orthopaedic Knowledge Update. AAOS; 2006:31-40.
8. Lombardi AV. Orthopaedic Secrets. In: Complications in Total Knee Arthroplasty. Philadelphia, Pa: Hanley and Belfus; 1999:306-308.
9. Stöckl B, Nogler M, Rosiek R, et al. Navigation improves accuracy of rotational alignment in total knee arthroplasty. *Clin Orthop Relat Res*. 2004; (426):180-186.
10. Chauhan SK, Scott RG, Breidahl W, et al. Computer assisted knee arthroplasty versus a conventional jig-based technique. *J Bone Joint Surg Br*. 2004; 86(3):372-377.
11. Siston RA, Patel JJ, Goodman SB, et al. The variability of femoral rotational alignment in TKA. *J Bone Joint Surg Am*. 2005; 87(10):2276-2280.
12. Picard F, Gregori A, Dean F, et al. Computer-assisted dynamic total knee arthroplasty using Whiteside's line for alignment [erratum in: *Orthopedics*. 2007; 30(4):327]. *Orthopedics*. 2006; 29(10 suppl):S104-S107.
13. Katz JN, Barret J, Mohamed NN, et al. Association between hospital and surgeon procedure volume and the outcomes of TKR. *J Bone Joint Surg Am*. 2004; 86-A(9): 1909-1916.
14. Katz JN, Bierbaum BE, Losina E. Case mix and outcomes of TKR in orthopaedic specialty hospital. *Med Care.* 2008; 46(5):476-480.
15. SooHoo NF, Lieberman JR, Ko CY, et al. Factors predicting complication rates following total knee replacement. *J Bone Joint Surg Am*. 2006; 88(3):480-485.
16. Siston RA, Giori NJ, Goodman SB, et al. Surgical navigation for total knee arthroplasty: a perspective. *J Biomech*. 2007; 40(4):728-735.
17. Bauwens K, Matthes G, Wich M, et al. Navigated total knee replacement. A meta-analysis. *J Bone Joint Surg Am*. 2007; 89(2):261-269.
18. Mason JB, Fehring TK, Estok R, et al. Meta-analysis of alignment outcomes in computer-assisted total knee arthroplasty surgery. *J Arthroplasty*. 2007; 22(8):1097-1106.
19. Lerat JL, Besse JL, Desmé D, et al. Accuracy of total knee replacement bone cuts using a conventional ancillary system: 300 Innex total knee arthroplasties [in French]. *Rev Chir Orthop Reparatrice Appar Mot*. 2006; 92(3):248-256.
20. Sundaram RO, Parkinson RW. Closed suction drains do not increase the blood transfusion rates in patients undergoing total knee arthroplasty. *Int Orthop*. 2007; 31(5):613-616. Epub 2006 Sep 1.
21. Kalairajah Y, Simpson D, Cossey AJ, et al. Blood loss after total knee replacement: effects of computer-assisted surgery. *J Bone Joint Surg Br*. 2005; 87(11):1480-1482.
22. Jenny JY, Clemens U, Kohler S, et al. Consistency of implantation of a total knee arthroplasty with a non-image-based navigation system: a case-control study of 235 cases compared with 235 conventionally implanted prostheses. *J Arthroplasty*. 2005; 20(7):832-839.
23. Jeffery RS, Morris RW, Denham RA. Coronal alignment after total knee replacement. *J Bone Joint Surg Br*. 1991; 73(5):709-714.
24. Sikorski JM, Blythe MC. Learning the vagaries of computer-assisted total knee replacement. *J Bone Joint Surg Br*. 2005; 87(7):903-910.
25. Callaghan JJ, Liu SS, Warth LC. Computer-assisted surgery: a wine before its time: in the affirmative. *J Arthroplasty*. 2006; 21(4 suppl 1):27-28.
26. Unitt L, Sambatakakis A, Johnstone D, Briggs TW. Short-term outcome in total knee replacement after soft-tissue release and balancing. *J Bone Joint Surg Br*. 2008; 90(2):159-165.
27. Peersman G, Laskin R, Davis J, Peterson M. The Insall Award paper - Infection in total knee replacement - A retrospective review of 6489 total knee replacements. *Clin Orthop Relat Res*. 2001; (392):15-23.

Columbus Primary Total Knee Replacement: A 2- to 4-Year Follow-up of the Use of Intraoperative Navigation-derived Data to Predict Pre- and Postoperative Function

S. David Stulberg, MD; Mark A. Yaffe, MD; Ritesh R. Shah, MD; Susan E. Gall-Sims, BS; Nicholas Palmese, BS; Michael A. Granieri, BS; Philip H. Schmidt, BS

abstract

The purpose of this study was to examine the clinical outcomes associated with the Columbus primary total knee replacement (B. Braun Aesculap, Tuttlingen, Germany), correlate these outcomes with variables measured intraoperatively with the OrthoPilot navigation system (B. Braun Aesculap), and explore the full potential of automating the process of intraoperative data collection. Clinical and functional outcomes at 2.5 years were similar to results reported in previous studies. Correlations were seen between initial mechanical axis deformity and postoperative range of motion as well as between final mechanical axis alignment and the presence of flexion contractures at later follow-up. It is now possible to potentially stratify particular segments of patients and develop specific intraoperative alignment targets that are most likely to yield positive clinical and functional outcomes.

Computer-assisted total knee replacement (TKR) has been shown to increase the precision and accuracy of implant alignment.[1-8] It is unclear, however, whether the potential improvements in implant alignment translate to improvements in implant durability or long-term clinical and functional outcomes. An intraoperative navigation system offers the potential to relate intraoperative variables, such as alignment, laxity, and soft tissue balance immediately before and after implant placement to long-term clinical and functional outcomes such as pain, range of motion (ROM), patient mobility, and movement independence. To our knowledge, there has not been a definitive examination of this relationship to date. Through the process of automation, it is possible to seamlessly translate the intraoperative data produced by the navigation system into a format that can be easily examined in relation to pre- and postoperative outcome measures. The purpose of this study was to examine the clinical and functional outcomes associated with the Columbus primary TKR (B. Braun Aesculap, Tuttlingen, Germany), correlate these with variables measured intraoperatively by the navigation system, and explore the full potential of automating the transfer of intraoperative limb and implant alignment data as measured with a computer-assisted navigation system.

Materials and Methods

We performed 58 consecutive computer-assisted TKAs on 51 patients. Aesculap primary, posterior cruciate retaining Columbus implants were inserted using the OrthoPilot (B. Braun Aesculap) image-free navigation instrumentation. Of these patients, 30 underwent unilateral computer-assisted surgery (CAS), 7 underwent bilateral CAS, and 14 underwent bilateral TKA with one side performed using CAS. Basic

Drs Stulberg, Yaffe, and Shah, and Susan E. Gall-Sims, Nicholas Palmese, Michael A. Granieri, and Philip H. Schmidt are from the Feinberg School of Medicine, Northwestern University, Chicago, Illinois.

Dr. Stulberg is a consultant for Aesculap. Drs Yaffe and Shah, Michael A. Granieri, and Philip H. Schmidt have no relevant financial relationships to disclose. ORTHOPEDICS *was unable to determine whether Susan E. Gall-Sims, or Nicholas Palmese have any relevant financial relationships to disclose or whether they are paid consultants for any companies.*

We would like to acknowledge Nicholas Palmese of EcomGlobalMedical, creator of OR Upload, for his assistance in this study.

Correspondence should be addressed to S. David Stulberg, MD, Professor of Clinical Orthopaedic Surgery, Northwestern University Feinberg School of Medicine, Director, Joint Reconstruction & Implant Service, Northwestern Memorial Hospital, 680 N Lake Shore Drive, Suite 1028, Chicago, IL 60610.

Table 1

Demographics

Patients		51	
Unilateral TKA (%)		51%	
Age (y)	Age (range)	65.7	(48.0-86.1)
Sex (% male)		31%	
Dx (% OA)		100%	
BMI Avg	BMI (range)	32.0	(22-52)

demographic information was obtained for each patient (Table 1). For each TKA, we obtained weight-bearing, full-length anteroposterior (AP) and short film lateral radiographs. The AP mechanical axis and sagittal femoral and tibial axis measurements were recorded, both intraoperatively using the navigation system and with standard 4-week (short-term) and 2-year (long-term) postoperative radiographs. Investigational review board permission was obtained for this study.

We obtained intraoperative navigation measurements preoperatively before any cuts were made and again postoperatively after cuts were made and implants placed. The target intraoperative alignment was 0º for the mechanical, femoral, and tibial axes. Through an automated process, the alignment results generated by the navigation system were compared with postoperative outcomes. Pre- and postoperative clinical examinations at 4 weeks, 6 months, 1 year, and 2 to 4 years were performed by a physician blinded to intraoperative measurements. Average follow-up was 2.5 years. The Knee Society Knee score, which is a composite from measures of ROM, pain, and knee stability, and the Knee Society Functional score, which is an assessment of patient mobility and movement independence, were evaluated according to the Knee Society scoring system. Six patients (all with unilateral TKA) were lost to follow-up due to relocation, unwillingness to continue participation in the study, or lack of intraoperative measurements. These patients were excluded from the final analysis of the data.

Table 2

Clinical and Functional Findings: Preoperative, 1-month Postoperative, and 2-year Postoperative

	CAS Group
Mechanical Axis[a]	
Preoperative	5.62º ± 5.2 (-12º-16º)
Postoperative	0.56º ± 1.0 (-1º-3º)
Flexion Contracture	
Preoperative	5.36º ± 4.95 (0º-15º)
1 mo postoperative	1.59º ± 2.71 (0º-13º)
2-y postoperative	0.31º ± 1.07 (0º-5º)
ROM	
Preoperative	114.2º ± 17.0 (60º-145º)
1-mo postoperative	101.8º ± 20.9 (0º-135º)
2-y postoperative	120.7º ± 13.1 (50º-140º)
Total Laxity[a]	
Preoperative	8.7º ± 3.0 (3º-16º)
Postoperative	2.7º ± 1.1 (0º to 6º)
Pain Score[b]	
Preoperative	13.3 ± 11.7 (0-50)
1-mo postoperative	27.4 ± 13.6 (0-50)
2-y postoperative	43.1 ± 12.5 (0-50)
Function Score	
Preoperative	47.5 ± 15.0 (5-80)
1-mo postoperative	46.8 ± 16.9 (5-85)
2-y postoperative	76.7 ± 23.9 (30-100)
Knee Score	
Preoperative	43.5 ± 19.2 (0-100)
1 mo postoperative	68.9 ± 18.0 (27-100)
2-y postoperative	88.5 ± 18.1 (21-100)

(30 Unilateral, 7 Bilateral, 14 Bilateral with One-side CAS)
[a]Navigation-generated intraoperative measurement.
[b]Pain score: 50 = no pain; 0 = maximum pain.

Table 3

Change in Clinical and Functional Outcome Measures (Preoperative to 2 y)

	Minimum	Maximum	Mean	SD
Knee Score	-26	97	48.37	25.96
Function Score	-10	95	29.66	24.05
Pain Score[a]	-20	50	31.25	15.69
ROM (in degrees)	-72	55	7.05	18.11

[a]Pain score, 50 = no pain; 0 = maximum pain

We used the Aesculap OrthoPilot navigation system for computer-assisted

Table 4

An Analysis of Radiographic and Navigation Measurement of Limb and Implant Alignment

Axis of Measurement	Measurement of Interest	Mean	Minimum	Maximum	SD
Mechanical Axis (Antero-posterior) (Varus +)	Preop **Radiograph**	8.76	-12	22	8.24
	Preop **Navigation**	5.62	-12	16	5.20
	Postop (1 mo) **Radiograph**	1.91	-4	8	2.89
	Postop (2 y) **Radiograph**	1.43	-2	4	1.91
	Postop **Navigation**	.56	-1	3	1.00
Femoral Axis (Sagittal) (Flexion, +)	Postop (1 mo) **Radiograph**	2.05	-4	7	2.46
	Postop (2 y) **Radiograph**	1.73	0	4	.961
	Postop **Navigation**	-.24	-2	2	.847
Tibial Axis (Sagittal) (Posterior Slope, -)	Postop (1 mo) **Radiograph**	-2.10	-7	2	1.80
	Postop (2 y) **Radiograph**	-2.93	-8	0	2.219
	Postop **Navigation**	-.76	-6	1	1.33

TKA and to generate navigation alignment measurements.

We used the ORUpload software system (EcomGlobalMedical Research and Development Inc, San Antonio, Texas) to automate the transfer and integration of intraoperative data collected by the navigation system to the postoperative data collection program.

A two-tailed bivariate Pearson correlation was used to evaluate the strength of the association between pre- and postoperative radiographic and navigation alignment measurements as well as the association of interobserver measurements. An analysis was performed on pre and postoperative navigation-generated alignment measurements as well as clinical and functional outcomes. Significance was considered $P < .05$. All statistical analyses were performed using SPSS version 14.0 statistical software (SPSS Inc, Chicago, Illinois).

RESULTS

At a mean follow-up of 2.5 years, patients exhibited mean Knee Society Knee scores (composite of pain, ROM, and knee stability) of 88.5 ± 18.1 (21 to 100), Knee Society Functional scores (composite of patient mobility and movement independence) of 76.7 ± 23.9 (30 to 100), Knee Society Pain scores of 43.1 ± 12.5 (0 to 50), ROM of 120.7º ± 13.1 (50º to 140º), and flexion contractures of 0.31º ± 1.0 (0º to 5º) (Table 2). Compared with preoperative values, patients exhibited mean increases in Knee Society Knee scores of 47.3 ± 25.9 (-26 to 97), Functional scores of 29.6 ± 24.0 (-10 to 95), Pain scores of 31.2 ± 15.6 (-20 to 50), and ROM of 7.0º ± 18.1 (-72º to 55º) (Table 3).

Mean preoperative mechanical axis measurements were 9.28º as measured on standard long-standing weight-bearing radiographs and 5.62º as measured by the navigation system while the patient was non-weight bearing and lying supine in the operating room. Mean postoperative mechanical axis measurements were 1.43º as measured by 2-year postoperative radiographs and 0.56º as measured by the navigation system once bone cuts were made and implants placed. Postoperative sagittal femoral flexion was 1.73º and posterior tibial slope was 2.93º as measured by 2-year radiographs and -0.24º and 0.76º, respectively, as measured by the navigation system (Table 4). The pre- and postoperative alignment and clinical and functional outcome measures of our study patient with the most no-

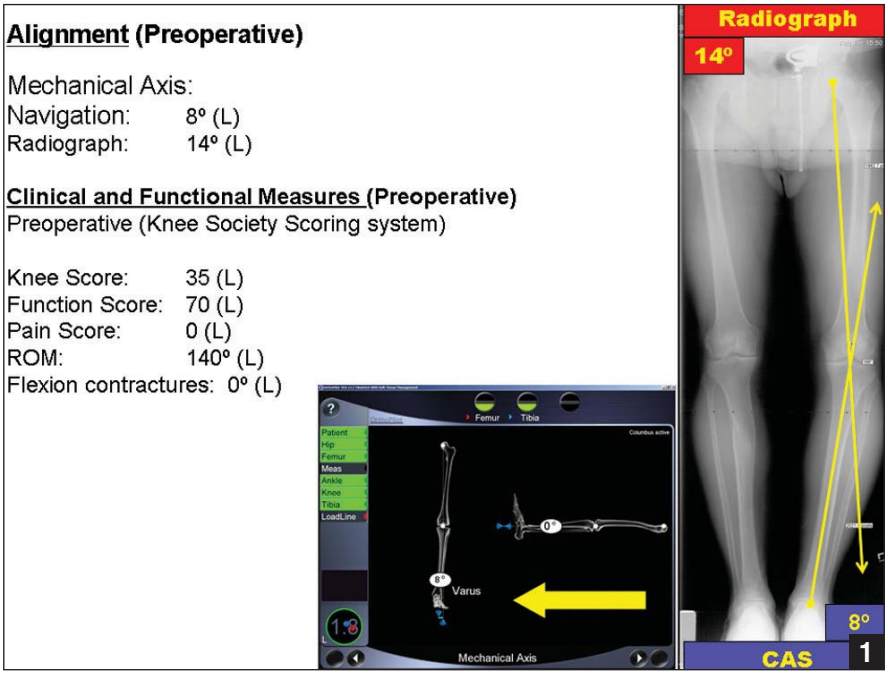

Figure 1: Preoperative alignment and clinical and functional outcome measures of study patient with the most notable preoperative limb deformities.

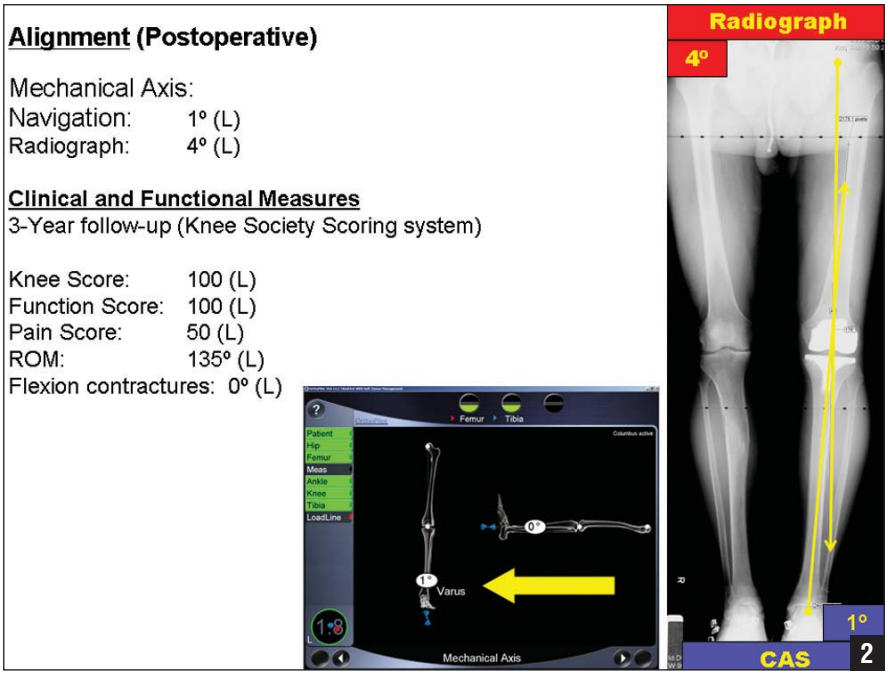

Figure 2: Postoperative alignment and clinical and functional outcome measures of study patient with the most notable preoperative limb deformities.

table preoperative limb deformities are presented in Figures 1 and 2.

An analysis of correlations between intraoperative navigation-generated variables and pre and postoperative (2 to 4 years) outcome measures were notable for (1) a statistically significant association between increased preoperative mechanical axis deviation and both a decreased absolute ROM (r = -0.438, P = .017), and increased ROM improvement (r = 0.482, P = .008) at 2 to 4 years; (2) a statistically significant association of increased preoperative flexion contracture with the presence and magnitude of a flexion contracture (r = 0.343, P = .035) at 2 to 4 years; (3) a statistically significant association of increased postoperative mechanical axis deviation and the presence and magnitude of flexion contractures (r = 0.653, P < .01) at 2 to 4 years, and (4) a statistically significant association between increased posterior tibial slope cut and increased postoperative laxity (r = 0.317, P = .032). An examination of additional correlations between intraoperative variables (laxity, mechanical axis, femoral and tibial cut axes) and postoperative outcomes (Knee Society Knee score, Function score, Pain score, ROM, and pre to postoperative changes in these variables) did not yield any statistically significant findings.

Discussion

The majority of studies that have assessed outcomes of CAS TKA have focused on alignment as the primary outcome measure rather than clinical and functional outcomes.[1-8] The alignment results reported in this study using the Columbus Knee System and the OrthoPilot navigation system are consistent with the results reported in these previous studies. Moreover, it appears that the Columbus CAS TKA generates clinical and functional outcomes that are comparable with previous studies that have evaluated these outcome measures in TKA performed using manual instrumentation.

Analysis of Outcomes

In our study, we found Knee Society Knee, Functional, and Pain scores of 88.5 ± 18.1 (21 to 100), 76.7 ± 23.9 (30 to

100), and 43.1 ± 12.5 (0 to 50), respectively. These results were similar to results seen by Kane et al., who found mean Knee scores of 80.0 to 82.4 in 57 published studies with average follow-up between 6 and 189 months.[9]

Similar results were reported by Spencer et al., who used a Duracon knee prosthesis (Stryker Orthopaedics, St. Leonards, Australia) and noted an average Knee Society composite score (combined Knee and Functional scores) of 156.4 ± 33.1.[10] Molfetta et al., used a Search-evolution prosthesis (B. Braun Aesculap) and found Knee and Functional scores of 84 ± 5.4 and 90 ± 5.3 at an average follow-up of 5.4 years, which were slightly greater in value and exhibited smaller standard deviations than the results of our current study.[11] Clayton et al. used the PFC Sigma prosthesis (Depuy, Johnson & Johnson, New Brunswick, NJ) and evaluated Knee, Functional, and Pain scores at 5-year follow-up.[12] He found postoperative Knee scores of 89.3 ± 12.1 (mean improvement, 58.4), Functional scores of 79.9 ± 19.2 (mean improvement, 31.6), and Pain scores of 46.2 ± 10.4. The Pain scores in particular are notably similar in magnitude to those in our study. Matsumoto et al. used the Vector Vision (Depuy-BrainLab, Heimstetten, Germany) and the PFC Sigma (Depuy, Warsaw, Ind) and found 2-year postoperative Knee scores of 84.5, Functional scores of 94.3, and ROM of 113.0 at follow-up of 27 months.[13] These results demonstrate superior functional scores but slightly lower knee scores and ROM compared to the present study. Average ROM in our study was 120.7º ± 13.1º (50º to 140º). These results were similar to those from Laskin et al., who found mean ROM of 118º in a 5-year follow-up of patients who were implanted with the Genesis II (Smith and Nephew, Memphis, Tenn).[14] Kim et al. used the PFC Sigma prosthesis (Depuy) and found Pain scores of 44 and ROM of 127º at an average follow-up of 2.6 years.[15]

Several investigators have reported the tendency for Knee and Function scores to decline over time.[9,11,16] Benjamin et al. found that improvements in Knee Society scores are not permanent.[16] Rather, declines were seen in clinical and functional measures after 3 years of follow-up, most notably in patients with pre-existing, symptomatic arthritis in the contralateral knee or other joints. Declines over time in Knee Society and Hospital for Special Surgery Scores were also noted by Kane et al.[9] Given this trend, some investigators have suggested that the optimal or most appropriate time to evaluate Knee scores is 5 years postoperatively.[11] Our average follow-up was 2.5 years, thus there may be a potential for patients to continue to achieve improvements in ROM, reductions in pain, and advances in mobility in continued follow-up.

Relation of Intraoperative Variables to Postoperative Function

Intraoperative navigation allows the surgeon to correlate intraoperative limb and implant measurements to pre and postoperative outcome measures. To our knowledge, there are no studies that have examined this type of relationship. There are, however, several studies that have investigated the impact of demographic and baseline functional data on postoperative outcomes. Stickles et al. found a trend toward improved WOMAC scores, compared with preoperative baseline scores, in patients with a higher body mass index (BMI).[17] Jones et al. found no significant relationship between preoperative pain status and age, sex, or BMI.18 They did report however, that significant preoperative pain was a positive predictor of postoperative pain. Konig et al. found a positive correlation between BMI and functional outcomes but no correlation between age, gender, or BMI to pain or overall Knee Society scores.[19]

In our study, we discovered a statistically significant relationship between several key intraoperative and postoperative variables. We discovered that patients with the most significant preoperative mechanical axis deformities achieved less absolute postoperative ROM at 2 to 4 years but experienced greater overall ROM improvements than did patients with less significant initial deformities. We also found a significant association between postoperative mechanical axis deviation and the magnitude of flexion contractures at 2 to 4 years. In addition, the presence of a preoperative flexion contracture was strongly associated with the continued presence of a flexion contracture postoperatively. Increased posterior tibial slope was also associated with greater total mediolateral laxity at the end of the procedure. These types of relationships may help to identify the factors that will affect clinical outcomes most significantly and may further help to identify the patients who would benefit most from the use of CAS during TKA. These types of relationships may help establish optimal alignment goals for patients with varying preoperative deformities and instabilities who undergo TKA.

Automation Process

Automation tools allow the surgeon to analyze patient data both intraoperatively and postoperatively in real time and may help to predict postoperative outcomes. The use of an intraoperative navigation system and the automated management of the information that this system provides is proving beneficial in helping us understand the relationship between intraoperative variables, cuts, and alignment and pre and postoperative outcome measures. The automation process begins with a software interface that electronically captures data generated by the navigation system with minimal effort by the surgeon. Information on alignment, laxity, ROM, and bone cuts is stored and available for analysis. This information is then transferred as automated file algorithms to directories and datasets specific to the field of research. The information can then be stratified

among a set of variable searching tools that macromanage the collected data. Physicians and staff use electronic data capturing (EDC) forms to enter clinical follow-up data directly into the patient record. Once entered, the data can be updated easily throughout the patient study timeline. The data is then available for immediate viewing, searching, and analysis. The system also has the ability to store and incorporate radiographic studies and measurements into the data evaluation, allowing real time evaluation of associations between specific alignment measures and clinical and functional outcomes. For example, a need to compare the correlation of preoperative mechanical axis measurements to postoperative Knee scores at 1 month and 2 years in patients with preoperative mechanical axis deviations ⩽3° versus patients with deviations ⩾5° can be accomplished in seconds. Given the considerable time to market acceptance of new medical technologies and devices, software automation tools have the potential to close the gap between physician-led studies and surgical innovations by streamlining and simplifying the process of data collection and analysis.

Conclusion

At an average of 2.5 years of follow-up, navigated TKA with the Columbus implant produced clinical and functional outcomes similar to those reported in previous studies.[9-12,14,15] The collection of intraoperative data through use of a navigation system allows for the establishment of a long-term database where one can easily analyze the relationship between intraoperative variables and pre and postoperative clinical and functional outcomes. Automation streamlines the data analysis process by electronically capturing intraoperative navigation-generated data and transforming it into a format that can be easily analyzed in relation to patient demographic variables, alignment measurements, and clinical and functional outcome measures. We are now able to stratify groups of patients, such as those with large initial deformities or flexion contractures, and develop intraoperative alignment targets most likely to yield positive clinical and patient-perceived functional outcomes.

References

1. Bathis H, Perlick L, Tingart M, Luring C, Zurakowski D, Grifka J. Alignment in total knee arthroplasty. A comparison of computer-assisted surgery with the conventional technique. *J Bone Joint Surg Br*. Jul 2004;86(5):682-687.
2. Chauhan SK, Scott RG, Breidahl W, Beaver RJ. Computer-assisted knee arthroplasty versus a conventional jig-based technique. A randomised, prospective trial. *J Bone Joint Surg Br*. Apr 2004;86(3):372-377.
3. Chin PL, Yang KY, Yeo SJ, Lo NN. Randomized control trial comparing radiographic total knee arthroplasty implant placement using computer navigation versus conventional technique. *J Arthroplasty*. Aug 2005;20(5):618-626.
4. Decking R, Markmann Y, Fuchs J, Puhl W, Scharf HP. Leg axis after computer-navigated total knee arthroplasty: a prospective randomized trial comparing computer-navigated and manual implantation. *J Arthroplasty*. Apr 2005;20(3):282-288.
5. Haaker RG, Stockheim M, Kamp M, Proff G, Breitenfelder J, Ottersbach A. Computer-assisted navigation increases precision of component placement in total knee arthroplasty. *Clin Orthop Relat Res*. Apr 2005(433):152-159.
6. Jenny JY, Boeri C. Computer-assisted implantation of a total knee arthroplasty: a case-controlled study in comparison with classical instrumentation. *Rev Chir Orthop Reparatrice Appar Mot*. Nov 2001;87(7):645-652.
7. Sparmann M, Wolke B, Czupalla H, Banzer D, Zink A. Positioning of total knee arthroplasty with and without navigation support. A prospective, randomised study. *J Bone Joint Surg Br*. Aug 2003;85(6):830-835.
8. Stockl B, Nogler M, Rosiek R, Fischer M, Krismer M, Kessler O. Navigation improves accuracy of rotational alignment in total knee arthroplasty. *Clin Orthop Relat Res*. Sep 2004(426):180-186.
9. Kane RL, Saleh KJ, Wilt TJ, Bershadsky B. The functional outcomes of total knee arthroplasty. *J Bone Joint Surg Am*. Aug 2005;87(8):1719-1724.
10. Spencer JM, Chauhan SK, Sloan K, Taylor A, Beaver RJ. Computer navigation versus conventional total knee replacement: no difference in functional results at two years. *J Bone Joint Surg Br*. Apr 2007;89(4):477-480.
11. Molfetta L, Caldo D. Computer navigation versus conventional implantation for varus knee total arthroplasty: a case-control study at 5 years follow-up. *Knee*. Mar 2008;15(2):75-79.
12. Clayton RA, Amin AK, Gaston MS, Brenkel IJ. Five-year results of the Sigma total knee arthroplasty. *Knee*. Oct 2006;13(5):359-364.
13. Matsumoto TT, N; Kurosaka, M; Muratsu, H; Yoshiya, S; Kuroda, R. Clinical Values in Computer-Assisted Total Knee Arthroplasty. *Orthopedics*. 2006;29(12).
14. Laskin RS, Davis J. Total knee replacement using the Genesis II prosthesis: a 5-year follow up study of the first 100 consecutive cases. *Knee*. Jun 2005;12(3):163-167.
15. Kim YH, Kim JS, Yoon SH. Alignment and orientation of the components in total knee replacement with and without navigation support: a prospective, randomised study. *J Bone Joint Surg Br*. Apr 2007;89(4):471-476.
16. Benjamin J, Johnson R, Porter S. Knee scores change with length of follow-up after total knee arthroplasty. *J Arthroplasty*. Oct 2003;18(7):867-871.
17. Stickles B, Phillips L, Brox WT, Owens B, Lanzer WL. Defining the relationship between obesity and total joint arthroplasty. *Obes Res*. Mar 2001;9(3):219-223.
18. Jones RE, Skedros JG, Chan AJ, Beauchamp DH, Harkins PC. Total knee arthroplasty using the S-ROM mobile-bearing hinge prosthesis. *J Arthroplasty*. Apr 2001;16(3):279-287.
19. Konig A, Kirschner S, Walther M, Eisert M, Eulert J. Hybrid total knee arthroplasty. *Arch Orthop Trauma Surg*. 1998;118(1-2):66-69.

Unicompartmental Knee Replacement: A Comparison of Four Techniques Combining Less Invasive Approach and Navigation

JEAN-YVES JENNY, MD

abstract

We developed a nonimage-guided navigation system for unicompartmental knee replacement, suitable for both conventional and minimally invasive approaches. We performed a radiologic analysis of the accuracy of implantation with conventional nonnavigated instrumentation, conventional, open navigated instrumentation, minimally invasive navigated experimental instrumentation derived from conventional instruments, and minimally invasive navigation-dedicated instrumentation. Navigated technique allowed improving the accuracy of the radiologic implantation. Minimally invasive implantation was effective, but the accuracy may not reach that of the conventional navigated technique. Minimal invasive techniques have to be validated, because a loss of accuracy will negatively influence long-term outcomes.

The accuracy of implantation is an accepted prognostic factor for the long-term survival of unicompartmental knee replacement (UKR).[1] However, most UKR systems offer limited and potentially inaccurate instrumentation that relies on substantial surgeon judgment for prosthesis placement. Rates of inaccurate implantation as high as 30% have been reported with conventional, free-hand instrumentation.[2] An intramedullary femoral guiding device can improve these results,[3] but does not allow reproducible optimal implantation.

Computer-assisted systems have been developed for total knee replacement (TKR) and have proved to allow a higher precision of implantation for such implants compared with conventional instruments.[4] The Ortho-Pilot system (B. Braun Aesculap, Tuttlingen, Germany) has also been validated in clinical use by a prospective, randomized study.[5] This system is considered nonimage based, because it relies only on an intraoperative kinematic analysis of the lower limb.

We developed an adaptation of this technique for unicompartmental knee prosthesis (UKP) implantation, without any extramedullary or intramedullary guiding device, suitable for both conventional and minimally invasive approaches. We hypothesized that the navigation system will allow for placement of the prosthesis in a better position than that accomplished with the conventional technique, and that the minimally invasive navigated approach will not decrease the accuracy of the procedure. This study reports the radiologic results of four groups of patients who underwent UKP implantation with conventional nonnavigated instrumentation: conventional open navigated instrumentation; minimally invasive navigated experimental instrumentation derived from conventional instruments; and minimally invasive navigation-dedicated instrumentation.

OPERATIVE TECHNIQUES

Conventional Nonnavigated Instrumentation

The conventional technique has been described more extensively elsewhere.[3] After a medial parapatellar approach, typically 18 cm in length, the tibial resection guide was fixed on an extramedullary rod, after visual alignment with the tibial axis on both coronal and sagittal planes. The guide was pinned on the tibia, and proximal tibial resection was performed with an oscillating saw, preserving the tibial attachment of both cruciates. The femoral canal was entered at the most proximal point of the intercondylar notch, and an intramedullary rod was fixed in the femoral canal, representing the femoral coronal and

Dr Jenny is from Hôpitaux Universitaires de Strasbourg, Centre de Chirurgie Orthopédique et de la Main, Strasbourg, France.

Dr Jenny receives royalties from and is a consultant for B. Braun Aesculap.

Correspondence should be addressed to: Jean-Yves Jenny, MD, Centre de Chirurgie Orthopédique et de la Main, 10 avenue Baumann, F – 67400 Illkirch-Graffenstaden, France.

sagittal anatomical axes. A distal femoral resection guide was fixed on this rod with a coronal orientation defined on preoperative long leg radiographs according to the angle between the mechanical axis and the anatomic axis of the femur, and distal femoral resections were performed with an oscillating saw. A second femoral guide was applied on this distal resection to perform the dorsal femoral resection and the chamfer resection.

Conventional Open Navigated Technique

The navigation system used is an intraoperative nonimage-based one (OrthoPilot; B. Braun Aesculap, Tuttlingen, Germany).[6] After a medial parapatellar approach, typically 18 cm in length, two infrared localizers were placed on screws in the distal femur and in the proximal tibia and one strapped on the dorsal part of the foot. The relative motion of two adjacent localizers was tracked by an infrared camera (Polaris; Northern Digital, Toronto, Canada). The dedicated software calculated the center of rotation of this movement and so defined the respective joint center of the hip, knee, and ankle joints. These centers were use to calculated the mechanical axes of both the femur and tibia in both the coronal and sagittal planes. A localizer was then fixed on tibial or femoral resection blocks, and the software displayed in real time the orientation of these blocks compared with the mechanical leg axes. The surgeon can fix the block with the desired orientation before performing the bony resection with a classical motorized saw blade. The trial implants were tested, and the definitive prosthesis was cemented if the test was satisfactory.

Minimally Invasive Experimental Navigated Technique

The same nonimage-based navigation system was used, but the instruments were modified to allow their placement through an 8-cm skin incision. However, the software had to be modified because the minimally invasive approach did not allow the direct palpation of the lateral femorotibial joint. The position of the lateral articular points was calculated by the software with help of the radiographic preoperative planning.

Minimally Invasive Navigation-dedicated Technique

This technique has been described more extensively elsewhere.[7] The software is basically the same as for the minimally invasive experimental navigated technique. The procedure begins with a quadriceps-sparing medial arthrotomy, typically 6 cm in length. Kinematic registration is performed as usual. Anatomic registration is limited to the medial femorotibial joint. The tibial resection guide is oriented using a hands-free technique. A navigated bow is fixed with two bicortical screws on the distal femur and oriented along the knee flexion-extension axis. On this bow, the distal and posterior resection guides are fixed and oriented according to the navigation system but not fixed directly within the joint. Resections are performed with a saw blade for the posterior resection and a burr for the distal resections.

Materials and Methods

Five hundred seventy-four patients have undergone a medial osteoarthritis at the investigators' institution from January 1996 to December 2006 with implantation of a UKR for medial osteoarthritis comprising 256 cases with the conventional manual technique (group A), 90 cases with the conventional navigated technique (group B), 108 cases with the experimental minimally invasive technique (group C), and 120 cases with the minimally invasive navigation-dedicated technique (group D), successively. Two different protheses were used, the Search UKR (B. Braun Aesculap) in groups A, B, and C, and the Univation UKR (B. Braun Aesculap) in group D. Both prostheses were designed to be implanted as follows: coronal femorotibial mechanical angle of 0º to 5º of remaining varus deformation, coronal orientation of the femoral component of 90º ± 2º compared with the coronal femoral mechanical axis, sagittal orientation of the femoral component of 90º ± 2º (Search) or 80º ± 2º (Univation) compared with the distal anterior femoral cortex, coronal orientation of the tibial component of 90º ± 2º compared with the coronal tibial mechanical axis, and sagittal orientation of the tibial component of 88º ± 2º compared with the proximal posterior tibial cortex. All patients underwent a complete radiologic examination in the first 3 months after the index procedure, with anteroposterior (AP) and lateral plain knee radiographs and AP and lateral long leg radiographs.

Thirty UKRs in each group were randomly selected and compared. The following angles were measured on long leg Radiographs by a single observer (J.Y.J.): mechanical femorotibial angle (normal = 0°, varus deformation was described with a positive angle); coronal orientation of the femoral component compared with the mechanical femoral axis (normal = 90°, varus deformation was described with an angle < 90°); sagittal orientation of the femoral component compared with the distal anterior femoral cortex (normal = 90°, flexion deformation was described with an angle < 90°); coronal orientation of the tibial component compared with the mechanical tibial axis (normal = 90°, varus deformation was described with an angle < 90°); and sagittal orientation of the tibial component compared with the proximal posterior tibial cortex (normal = 90°, flexion deformation was described with angle < 90°).

Individual analysis was performed as follows: one point was given for each fulfilled item, giving a maximal accuracy note of 5 points. The accuracy note was compared among all groups with an ANOVA test with post-hoc Bonferrini-Dunn correction. Prosthesis implantation was considered satisfactory when the accuracy note was 5 (all fulfilled items); the rate of satisfactory implanted prostheses was compared in all groups with a chi-square test. Mean angular values in all groups were compared for each criterion with an ANOVA test with post-hoc Bonferrini-Dunn correction; the sagittal orientation of the femoral component of the

Table 1

Radiographic Results[a]

	Group A (n = 30)	Group B (n = 30)	Group C (n = 30)	Group D (n = 30)
Global accuracy note	1.5	4.5	3.3	4.2
	5	5	5	5
	0	3	2	3
	1.2	0.6	1.2	1.1
Coronal femorotibial mechanical angle	0.9	1.5	1.3	2.6
	7	5	8	6
	-6	-4	-8	-3
	4	2.2	2.1	2.7
Coronal orientation of the femoral component	88	89.1	91.1	88
	95	92	100	93
	82	85	76	86
	2.9	1.4	5	3
Sagittal orientation of the femoral component	89.3	89.6	87.6	81.6
	97	92	96	87
	78	86	78	74
	2.8	1.6	3.5	4.2
Coronal orientation of the tibial component	88.2	89.1	91.1	87.8
	96	92	94	94
	79	86	83	85
	2.6	1.4	5	2.7
Sagittal orientation of the tibial component	86.4	89.6	87.6	87.8
	96	93	92	92
	82	86	84	86
	3.2	1.3	3.5	2.9

[a]*Radiographic results in degrees (mean, maximum, minimum, SD).*

group D was corrected to compensate for the different goal. The rate of prostheses implanted within the desired range for each criterion was also compared in all groups with a chi-square test. All statistical tests were performed with a .05 limit of significance.

RESULTS

A total of 120 patients were selected (45 men); mean age was 67 years (SD, 6). Mean body mass index was 29.6 (SD, 4.5). Preoperative pain Knee Society Score (KSS) was 56 points (SD, 12), and preoperative functional KSS was 61 points (SD, 12). Mean preoperative coronal femorotibial mechanical angle was 7.8º (SD, 5.1). There were 54 grade 2, 59 grade 3, and 7 grade 4 degenerative changes according to Ahlback.[8] There were no significant differences in any preoperative parameter among all groups.

Radiographic results at the early follow-up are reported in Tables 1 and 2.

Mean global accuracy note was 1.5 (SD, 1.2) in group A, 4.5 (SD, 0.6) in group B, 3.3 (SD, 1.2) in group C, and 4.2 (SD, 1.1) in group D ($P < .001$). The rate of perfect implantation was 6/30 in group A, 18/30 in group B, 13/30 in group C, and 18/30 in group D ($P < .001$). Mean femorotibial angle was 0.9º (SD, 4.0) in group A, 1.5º (SD, 2.2) in group B, 1.3º (SD, 2.1) in group C, and 2.6º (SD, 2.7) in group D (NS). The rate of fulfilled item was 20/30 in group A, 25/30 in group B, 22/30 in group C, and 26/30 in group D (NS).

Mean coronal orientation of the femoral component was 88.0º (SD, 2.9) in group A, 89.1º (SD, 1.4) in group B, 91.1º (SD, 5.0) in group C, and 88.0º (SD, 3.0) in group D (NS). The rate of fulfilled item was 21/30 in group A, 26/30 in group B, 23/30 in group C, and 27/30 in group D (NS).

Mean sagittal orientation of the femoral component was 89.3º (SD, 2.8) in group A, 89.6º (SD, 1.6) in group B, 87.6º (SD, 3.5) in group C, and 81.6º (SD, 4.2) in group D (NS). The rate of fulfilled item was 21/30 in group A, 27/30 in group B, 21/30 in group C, and 26/30 in group D (NS).

Mean coronal orientation of the tibial component was 88.2º (SD, 2.6) in group A, 89.1º (SD, 1.4) in group B, 91.1º (SD, 5.0)

Table 2

Radiographic Results[a]

	Group A (n = 30)	Group B (n = 30)	Group C (n = 30)	Group D (n = 30)
Global accuracy note	6	18	13	18
Coronal femorotibial mechanical angle	20	25	22	26
Coronal orientation of the femoral component	21	26	23	27
Sagittal orientation of the femoral component	21	27	21	26
Coronal orientation of the tibial component	22	28	24	26
Sagittal orientation of the tibial component	21	28	24	26

[a]*Radiographic results in number of prostheses in the desired angular range.*

in group C, and 87.8º (SD, 2.7) in group D (NS). The rate of fulfilled item was 22/30 in group A, 28/30 in group B, 24/30 in group C, and 26/30 in group D (NS).

Mean sagittal orientation of the tibial component was 86.4º (SD, 3.2) in group A, 89.6º (SD, 1.3) in group B, 87.6º (SD, 3.5) in group C, and 87.8º (SD, 2.9) in group D (NS). The rate of fulfilled item was 21/30 in group A, 28/30 in group B, 24/30 in group C, and 26/30 in group D (NS).

Subgroup analysis showed a significant difference between global accuracy note in group A vs group B ($P < .001$), group C ($P = .05$), and group D ($P < .001$) and between rate of perfect implantation in group A vs group B ($P < .001$), group C ($P = .05$), and group D ($P < .001$).

All other subgroup differences were not significant.

Discussion

The restoration of the physiologic alignment of the lower limb is an accepted prognostic factor for long-term survival of a TKR.[9] Navigation systems have proven to improve the accuracy of implantation of a TKR.[4-6,10] The precision of the system used was experimentally calculated to be of 1° for angle measurement and of 1 mm for distance measurement.[11] However, outliers still can occur. There are several possible additional reasons for the observed errors including lack of precision of the radiologic measurement technique, lack of rigid fixation of the resection block on the bone, and lack of precise guiding of the saw blade by the resection blocks bending of the saw blade.[12] These causes of errors are inherent in all systems; however, a modification of the reference software should not introduce other causes of errors.

UKR is a valuable alternative to high tibial osteotomy[13] or TKR for the treatment of isolated medial osteoarthritis.[14] However, the exact indications are still controversial, because some investigators have reported a low survival rate of such implants.[15] Inaccurate implantation is a known factor for early failure.[1] There is no general agreement on the ideal positioning of a UKR, and the positioning we wanted to achieve can only be seen as a personal opinion. However, the goal of an instrumentation is to allow surgeons to place the prosthesis in the position they choose. It is then valuable to compare the positioning of the three groups of UKR implantation techniques, which were expected to implant the prosthesis in the same position, whatever this position should be. Most instrumentation offers imprecise guiding systems depends primarily on the surgeon's skill.[16] Even intramedullary guiding systems do not offer reproducible optimal implantation technique.[3]

The conventional navigated instrumentation used in this study is similar to that used for TKR implantation. It has been shown to allow achieving a significantly more accurate implantation measured on postoperative radiographs compared with the manual technique. The accuracy of implantation was similar to that obtained with the reference TKR software.

The conventional manual and navigation techniques involve conventional skin incision and approach, with splitting of the vastus medialis and lateral subluxation of the patella. We developed a navigated minimally invasive technique, which allows performing the entire procedure through a shorter skin incision. Our first experience is interesting. All procedures succeeded with a 5- to 10-cm skin incision. We observed a trend toward decreased accuracy of implantation of the prosthesis with the experimental minimally invasive navigated technique (group C). The calculation of the location of the anatomic point was less precise than the direct palpation, and this point has been addressed in the development of the software. The results of the last version of the software (group D) seem to be as satisfactory as for the reference group with open navigated technique (group B).

We did not yet study the influence of the minimally invasive approach on reha-

bilitation time. This point has already been investigated, and minimally invasive procedures might allow an earlier discharge and faster rehabilitation.[17]

Follow-up for the navigated prostheses is currently too short to know whether clinical outcome or survival rates will be improved. Longer follow-up is required to determine the respective advantages and disadvantages of this techniques and the potential benefit of a minimally invasive implantation.

CONCLUSION

Navigated implantation of a UKR with the nonimage-based system used allowed improvement of the accuracy of the radiologic implantation without significant inconvenience and with little change in the conventional operative technique. Minimally invasive implantation was effective, but the accuracy may not reach that of the conventional navigated technique. Minimally invasive techniques have to be validated, because a loss of accuracy will negatively influence long-term outcomes.

REFERENCES

1. Cartier P, Sanouillier JL, Grelsamer RP. Unicompartmental knee arthroplasty surgery. 10-year minimum follow-up period. *J Arthroplasty*. 1996;11 (7):782-788.
2. Tabor OB Jr, Tabor OB. Unicompartmental arthroplasty: a long-term follow-up study. *J Arthroplasty*. 1998;13 (4):373-379.
3. Jenny JY, Boeri C. Accuracy of implantation of a unicompartmental total knee arthroplasty with 2 different instrumentations: a case-controlled comparative study. *J Arthroplasty*. 2002;17(8):1016-1620.
4. Victor J, Hoste D. Image-based computer-assisted total knee arthroplasty leads to lower variability in coronal alignment. *Clin Orthop Relat Res*. 2004;(428):131-139.
5. Saragaglia D, Picard F, Chaussard C, Montbarbon E, Leitner F, Cinquin P. Mise en place des prothèses totales du genou assistée par ordinateur: comparaison avec la technique conventionnelle. *Rev Chir Orthop*. 2001;87(1):18-28.
6. Jenny JY, Boeri C. Unicompartmental knee prosthesis implantation with a non-image-based navigation system: rationale, technique, case-control comparative study with a conventional instrumented implantation. *Knee Surg Sports Traumatol Arthrosc*. 2003;11(1):40-45.
7. Jenny JY, Ciobanu E, Boeri C. The rationale for navigated minimally invasive unicompartmental knee replacement. *Clin Orthop Relat Res*. 2007;463:58-62.
8. Ahlback S. Osteoarthrosis of the knee. A radiographic investigation. Acta Radiol Diagn (Stockh). 1968; suppl.277; 1-72.
9. Jeffery RS, Morris RW, Denham RA. Coronal alignment after total knee replacement. *J Bone Joint Surg Br*. 1991;73(5):709-714.
10. Jenny JY, Boeri C. Implantation d'une prothèse totale de genou assistée par ordinateur. Etude comparative cas-témoin avec une instrumentation traditionnelle. *Rev Chir Orthop*. 2001;87(7):645-652.
11. Delp SL, Stulberg SD, Davies B, Picard F, Leitner F. Computer assisted knee replacement. *Clin Orthop Relat Res*.1998; (354):49-56.
12. Plaskos C, Hodgson AJ, Inkpen K, McGRaw RW. Bone cutting errors in total knee arthroplasty. *J Arthroplasty*. 2002;17(6):698-705.
13. Schai PA, Suh JT, Thornhill TS, Scott RD. Unicompartmental knee arthroplasty in middle-aged patients: a 2- to 6-year follow-up evaluation. *J Arthroplasty*. 1998;13 (4):365-372.
14. Newman JH, Ackroyd CE, Shah NA. Unicompartmental or total knee replacement? Five-year results of a prospective, randomized trial of 102 osteoarthritic knees with unicompartmental arthritis. *J Bone Joint Surg Br*. 1998;80(5):862-865.
15. Bert JM. 10-year survivorship of metal-backed, unicompartmental arthroplasty. *J Arthroplasty*. 1998;13 (8):901-905.
16. Argenson JN, Chevrol-Benkeddache Y, Aubaniac JM. Modern unicompartmental knee arthroplasty with cement: a three to ten-year follow-up study. *J Bone Joint Surg Am*. 2002;84(12):2235-2239.
17. Price AJ, Webb J, Topf H, Dodd CA, Goodfellow JW, Murray DW. Rapid recovery after Oxford unicompartmental arthroplasty through a short incision. *J Arthroplasty*. 2001;16(8):970-976.

Analysis of the Patellofemoral Congruence Angle According to the Rotational Alignment of the Femoral Component in Navigation-guided TKA

YOUNG-WAN MOON, MD; JAI-GON SEO, MD; JAE-HYUK YANG, MD; MIN-SOO SHON, MD

abstract

The relative femoral resection plane from the posterior condylar axis was determined by the navigation system. The investigators found that there was a relatively variable range of femoral component rotation intraoperatively (0º-6º) and attempted to determine whether this would affect postoperative patellofemoral congruence. Forty-six varus knees from 34 patients were included in the study; group 1 (15 knees) with 0º or 1º and group 2 (31 knees) with 3º to 6º. The mean (P = .855) and percentage of abnormal values (patellofemoral congruence angle >16º) (P = .193) in preoperative radiographs showed no significant differences between the two groups. In postoperative findings, the mean of patellofemoral congruence angles in group 1 (20.5º) showed a higher tendency than that in group 2 (14.1º), but no statistically significant difference between two groups (P = .089). In conclusion, there was no statistically significant difference in patellofemoral congruence between 2 groups.

Patellofemoral instability is a common problem after total knee arthroplasty (TKA). The incidence of patellofemoral instability after TKA has historically been between 10% and 35%, but with recent improvements in surgical technique, instrumentation, and prosthetic design, these rates have fallen to 1% to 12%.[1-3]

Despite advances in surgical technique and implant design, complications involving patellofemoral joint after TKA continue to be the primary cause of pain and the most often cited reason for revision TKA surgery.[1,3,4] Many factors have been implicated as causes of patellofemoral complications after TKA, including preoperative patellar tilt, component design, preparation of the patella, soft tissue balance of patellofemoral joint, surgical approach, and rotational alignment of the femoral component.[1,4]

It has been accepted that internal rotation of the component (femur and tibia) is directly related to the severity of patellofemoral complications.[3,4] Even small amounts of internal rotation (1º-4º) are correlated with lateral tracking and patellar tilting.[4] Higher degrees of internal rotation are related to patellar subluxation and early patellar dislocation.

Navigation-assisted knee surgery has been shown to improve axial alignment and component position.[5,6] Not only can navigation systems monitor sequential ligament release,[7] they can also measure extension-flexion gaps.[8] Whereas femoral component rotational position is adjusted by the ligament balancing gap method, these quantitative data can be monitored intraoperatively in real time. In this study, relatively variable range of external rotation was obtained by positioning the femoral component with ligament balancing gap technique using a navigation system. By dividing the patients into 2 groups — 0º or 1º and 3º to 6º — of external rotation, we evaluated the postoperative congruency angle of patellar.

MATERIALS AND METHODS

Between September 2004 and January 2007, 46 total knee arthroplasty (TKA) procedures were performed in 34 patients by a single surgeon (Y.W.M)

Drs Moon, Seo, Yang, and Shon are from the Department of Orthopedic Surgery, Samsung Medical Center, Sungkyunkwan University School of Medicine, Seoul, Korea.

Drs Moon, Seo, Yang, and Shon have no relevant financial relationships to disclose.

The authors thank Ms. Min-Jung Lee for her illustrations.

Correspondence should be addressed to: Jae-Hyuk Yang, MD, Department of Orthopaedic Surgery, Samsung Medical Center, Sungkyunkwan University School of Medicine, Ilwon-Dong 50, Kangnam-Gu, Seoul 135-710, Korea.

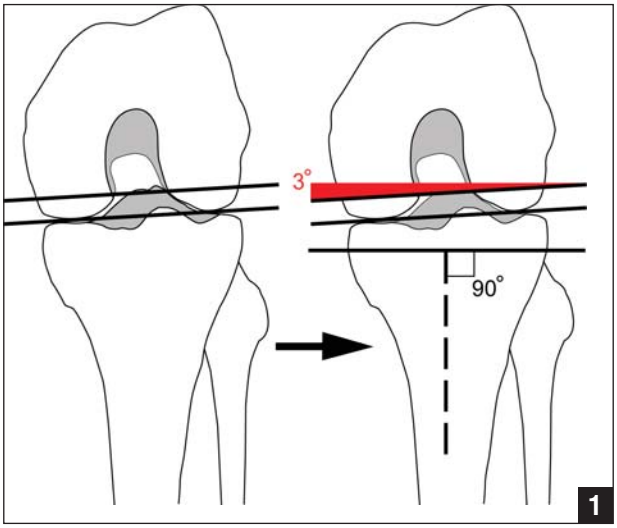

Figure 1: Surgical technique resects the proximal tibial surface perpendicular to the mechanical axis of the tibia and resects the posterior condyles to create a rectangular flexion space.

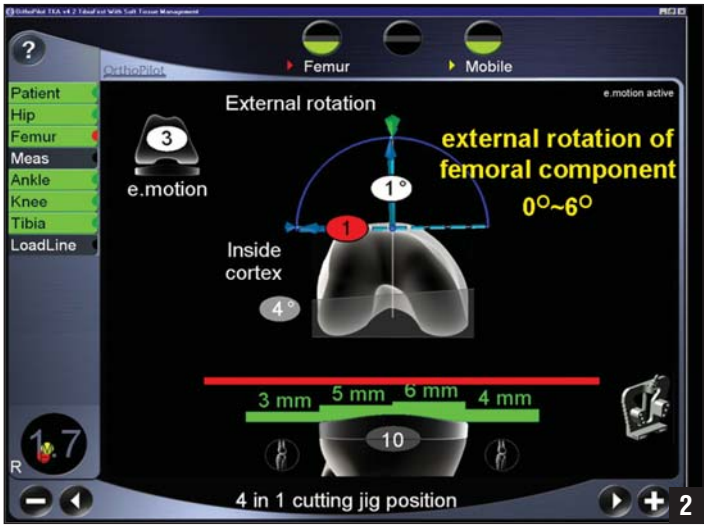

Figure 2: For rectangular flexion gap, various degrees of external rotation (0°-6°) of the femoral component were adopted relative to the posterior condylar axis.

with gap technique using the navigation system. Patients included two men (2 knees), and mean age was 66.9 years (range, 51-80). The preoperative diagnosis was osteoarthritis in 44 knees and osteonecrosis in 2 knees. All cases showed varus alignment in preoperative mechanical axis alignments.

TKA was performed using a navigation system (OrthoPilot; B. Braun Aesculap, Tuttlingen, Germany). This navigation system is an image-free system that uses kinematic analysis of the hip, ankle, and knee joints and anatomic mapping of the knee joint to construct a working model of a patient's knee.

Implants used in group 1 were E.motion PS (Posterior Stabilizing; B. Braun Aesculap) in 3 cases, e.motion FP (Floating Platform; B. Braun Aesculap) in 4 cases, and E.motion UC (Ultra-Congruency; B. Braun Aesculap) in 8 cases. Implants used in group 2 were e.motion PS in 7 cases, e.motion FP in 15 cases, and E.motion UC in 9 cases.

The surgical approach was a standard median parapatellar incision. The patellar was subluxated laterally and the tibia was subluxated anteriorly. The posterior cruciate ligaments were preserved or sacrificed based on the component used. The medial meniscus and the osteophytes were removed. Soft tissue balancing was carried out before any bone cuts were made. The arrays of the computer navigation system (OrthoPilot) were set up by means of femoral tracker, mounted to a screw. A screw (1 pin) was fixed to the medial aspect of the femur and the tibia, respectively. The position of the selected points required for the system was registered. The center of the proximal tibia was visually identified, and its coordinates were put into the computer by using the pointer specific to the navigation system used. After these localizations, the tibial mechanical axis was determined by a line joining the center of the proximal tibia and the calculated center of the ankle joint. After marking all the reference points, the correction of varus deformity to neutral axis was carried out by medial release in extension position. Limb alignment was checked by navigation system achieving neutral axis. Further soft tissue release and removal of posterior osteophytes were done if necessary at this stage.

Proximal tibial cutting was carried out first at a plane perpendicular to the mechanical axis in the tibia. A laminar spreader, which could adjust the medial and lateral compartments separately, was inserted to identify the adequate collateral tension in extension and 90º of flexion position. These coordinates were recorded, and the femoral cutting block was oriented accordingly to achieve equal extension and flexion gaps (Figure 1). Various degrees of external rotation from 0º to 6º relative to the posterior condylar axis of the femoral component were adopted (Figure 2).

Patellar tracking was tested intraoperatively after implantation by towel clip method. None of the cases showed subluxation or maltracking, and thus the lateral retinacular release was not necessary.

To evaluate, we categorized patients into two groups. In group 1 (15 knees), the adopted external rotation of the femoral component was 0º or 1º and in group 2 (31 knees), the range was 3º to 6º in respect to the posterior condylar axis. Patient demographic data are shown in Table 1, and the number of patients in each femoral external rotation degrees relative to the posterior condylar axis shown by the navigation system intraoperatively is shown on Table 2.

Because the patella was not resurfaced in any case, the postoperative patellofemoral

congruence angle could be measured. Patellofemoral congruence angles in this study were measured by Merchant's view at a fixed angle of 45º in flexed knee in the flexed knee position in pre- and postoperative radiographs (Figure 3). Any congruence angle greater than +16º was defined as abnormal. The angles measured were evaluated by an observer who was blinded to the surgical technique.

For comparing pre- and postoperative patellofemoral congruency angles between the two groups, paired the *t* test and Wilcoxon two-sample test were performed. Values of $P < .05$ were considered to be statistically significant. Analysis of the data was performed using SAS, version 9.1 (Cary, North Carolina).

Results

The mean preoperative patellofemoral congruence angles were 12.4º (range, 0.13º-47.1º) in group 1 and 9.5º (range, 0.13º-37º) in group 2. Postoperative mean patellofemoral congruence angles in group 1 (20.5º; range, 1.2º-47º) showed a higher values than those in group 2 (14.1º; range, -2.7º-38.4º), but without statistical significance ($P = .089$) (Figure 4).

The percentages of abnormal preoperative values (patellofemoral congruency angle >16º) were 26.7 % in group 1 and 6.5% in group 2. The mean ($P = .855$) and percentage of abnormal values ($P = .193$) in preoperative radiographs showed no significant differences between the two groups. Moreover, the percentage of abnormal postoperative values in each group (66.7% and 41.7%, respectively) showed no statistically significant difference between the 2 groups ($P = .116$) (Table 3).

Table 1

Patient Demographic Data

	Group 1	Group 2
Number of patients:	15	31
Age		
Mean ± SD	69.73 ± 4.95	65.52 ± 6.96
Range	63-80	51-79
Female (%)	100	93.5
Preoperative (KSS):		
Knee score		
Mean ± SD	50.27 ± 12.03	47.19 ± 12.95
Range	28-63	28-74
Functional score		
Mean ± SD	48.33 ± 12.77	47.97 ± 14.24
Range	30-70	10-80
Preoperative		(range, 0-145)
Flexion contracture		
Mean ± SD	9.33 ± 6.23	9.68 ± 6.82
Range	0-20	0-25
Further flexion		
Mean ± SD	131 ± 17.44	134.19 ± 11.04
Range	90-140	90-145
Diagnosis		
Osteoarthritis	15	29
Osteonecrosis	0	2
Others	0	0
Mean alignment deviation[a]		
Mean ± SD	12.47 ± 4.02	10.52 ± 4.46
Range	5-21	5-20
Type of implant		
E.motion PS	3	7
E.motion FP	4	15
E.motion UC	8	9

[a]*All cases were varus deformity.*

Discussion

The stability of the patellofemoral joint is directly affected by several factors, including preoperative patellar tilt; prosthetic component positioning and resultant limb alignment; preparation of the patella; prosthetic design; soft tissue balance; and surgical approach.[3,9,10]

The rotational alignment of the femoral and tibial components is one of the most important factors influencing patellofemoral stability because malrotation is one of the most common causes of patellofemoral complications.[11-15] Also, malrotation of the femoral or tibial components has been shown to be a cause of chronic pain with a potential for the patient to develop arthrofibrosis. Specifically for the femoral component, malrotation may lead to patellar instability, ligamentous instability, disturbed functional joint kinematics, and chronic anterior pain.[4,15,16]

The rotational alignment of the femoral component parallel to the transepicondylar axis is known to result in normal patellar tracking, more physiologic ligamentous bal-

Table 2

Degrees of External Rotation of the Femoral Component Relative to the Posterior Condylar Axis

Femoral external rotation	Group 1	Group 2
0º	8	
1º	7	
2º		
3º		6
4º		9
5º		12
6º		4
Number of cases	15	31

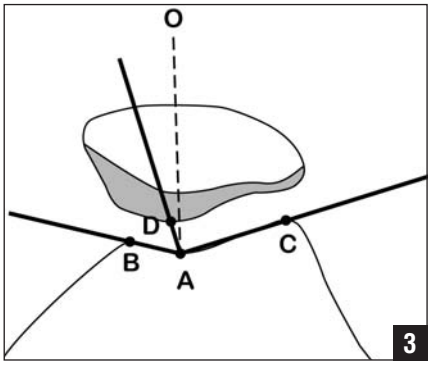

Figure 3: Patellofemoral congruence angle. Find the highest point of the medial (B) and lateral (C) condyles and the lowest point of the intercondylar sulcus (A). The angle, BAC, is the sulcus angle. Bisect the sulcus angel to establish the zero reference line, AO. Find the lowest point on the articular ridge of the patella (D). Project line AD. The angle DAO is the congruence angle. All values medial to the zero reference line AO are designated as minus and those lateral as plus.

ance, and minimized patellofemoral shear forces early in flexion.[10,14,17] Thus, most total knee instrument systems in varus or normal alignment have adopted 3º of external rotation relative to the posterior condylar axis to compensate for the nonparallel flexion gap that occurs when the posterior condylar axis is used to determine rotation.

The external rotation of the femoral component is thought to be necessary to compensate for the angular discrepancy that result from the proximal tibial cut perpendicular to the tibial shaft axis because the tibial articular plane is in approximately 3º varus from the tibia shaft axis in normal knees. Insall was the first to describe externally rotating the anterior and posterior femoral resections to correct limb alignment. Rhoads et al[2] and Anouchi et al[11] showed, in studies using anatomic specimen knees, that external rotation of the femoral component makes the patellar tracking close to that of the physiologic knee and significantly improves patellar tracking and reduces patellofemoral complications after TKA. Laskin[18] has introduced the clinical study that the mean degree of external rotation of the posterior femoral resections required to form a rectangular flexion space was 3º to 5º relative to the posterior condylar axis.

In 1998, Berger et al[4] analyzed the rotational alignment of TKA components in patients with normal mechanical axial alignment by computed tomography (CT) and found that the excessive combined internal rotation of femoral and tibial components correlated directly with the severity of the patellofemoral complication. Small amounts of combined internal rotation (1-4º) correlated with lateral tracking and patellar tilting. Moderate combined internal rotation (3-8º) correlated with patellar subluxation. Large amounts of combined internal rotational (7-17º) correlated with early patellar dislocation or late patellar prosthesis failure. Interestingly, there were no complications in patients with combined external component rotation up to 10º.[4] Akagi et al[13,14] concluded that the external rotation setting of the femoral component diminished the need for lateral retinacular release and may decrease the rate of patellofemoral complications that occur after TKA. These investigators suggested that setting the femoral component with an external rotation of 3º to 6º relative to the posterior condylar axis is appropriate in a knee with common varus or neutral alignment to set it parallel to the transepicondylar axis. Several studies[2,11,13] showed that additional external rotation of the femoral component from 3º to 10º more than the posterior condylar axis resulted in improved patellofemoral tracking. Miller et al[10] suggest that femoral component rotation parallel to the epicondylar axis resulted in the most normal patellar tracking and minimized patellofemoral shear forces early in flexion.

Several reports[16,19,20] suggest that the transepicondylar axis most consistently recreates a balanced flexion space and normal patellofemoral tracking. Although the ideal reference anatomic axis for femoral component rotation is still in debate, we have chosen the posterior condylar axis as a reference axis. Compared with the transepicondylar axis and Whiteside's line (anteroposterior line), the posterior condylar line was easily identified intraoperatively and therefore many instruments are designed to align the femoral component in 3 to 5º of external rotation from the posterior condylar line because previous studies have shown that transepicondylar axis is externally rotated from the posterior condylar tangent in 3º to 6º.[14,21,22]

In this study, various degrees of external rotation of the femoral component were adopted to achieve rectangular flexion gap from 0º to 6º relative to the posterior condylar line. There is a tendency for the femoral component to be placed in an internally rotated position in varus

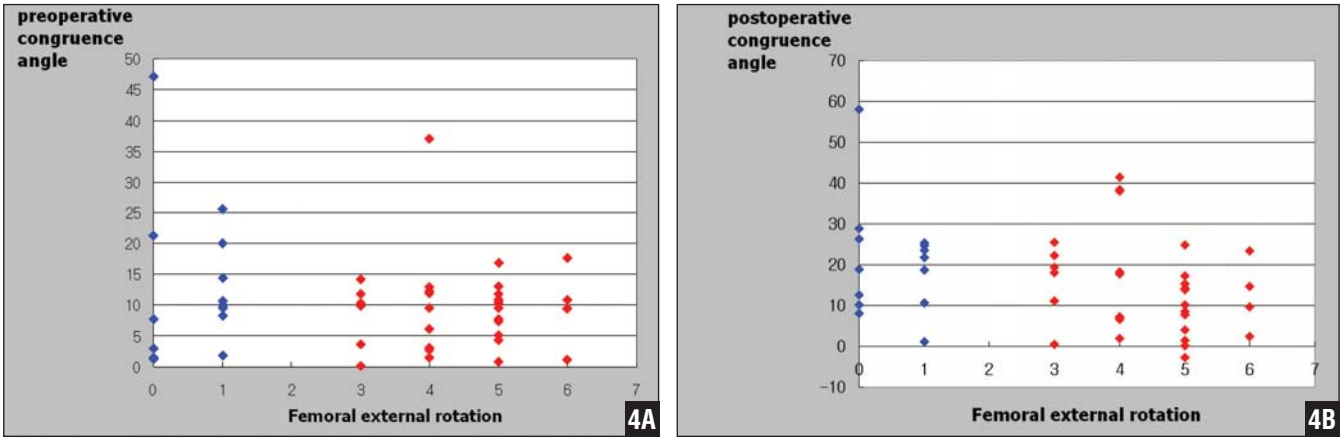

Figure 4: A, The distribution of preoperative and (B) postoperative patellofemoral congruence angles according to various degrees of external rotation of the femoral component (blue diamonds, group 1; red diamonds, group 2).

knees.[7,23] By medial release, and to make rectangular flexion gap simultaneously, the femoral component tends to rotate internally by 0º or 1º. Researchers were curious about whether differences in external rotation of femoral component in respect to posterior condylar line affect the postoperative patellofemoral tracking. By dividing the patients into two groups (group 1, 0º or 1º and group 2, 3-6º of femoral component rotation, although the mean and percentage of abnormal values of patellofemoral congruence angles in group 1 showed a higher tendency than in group 2), there were no statistically significant differences between the two groups.

Table 3

Percentage of Abnormal Values in the Patellofemoral Congruence Angle

Congruency Angle		Group 1 (n = 15)	Group 2 (n = 31)
Preoperative	No. of normal	11	29
	No. of abnormal	4	2
	Percentage of abnormal	26.7%	6.5%
Postopoperative	No. of normal	5	20
	No. of abnormal	10	11
	Percentage of abnormal	66.7%	41.9%

Managing the ideal axial alignment and correct balancing at the same time are the most difficult aspects of TKA and are primarily dependent on the skill and experience of the surgeon. Although many surgeons are concerned about navigation use as an additional procedure and about increased operation time, instrumentation cost, and additional equipment in operation room, the use of computer technology is no more cumbersome or complicated and provides surgeons with immediate and accurate feedback that are not available with conventional instrumentation. Computer navigation-assisted surgery offers reliable tools to consistently locate important knee and lower limb landmarks, allowing accurate bone cut level and orientation. New versions of navigation systems may also quantify the soft tissue tensional status by use of variable-sized spacer blocks or tensioners. These devices can monitor the soft tissue release sequentially and actually measure the flexion-extension gaps.[8]

There are several limitations to this study. First, the patellofemoral congruence evaluated was based on radiographic measurement on Merchant view at a fixed angle of 45º in the flexed knee. The sensitivity of radiographic assessment of limb and implant alignment may not be as great as that of CT. Computed tomography has been shown to be a more sensitive and accurate method of determining alignment measurements and of assessing component positioning.[4,24] Also, the radiographic measurement on Merchant view at a fixed angle of 45º in the flexed knee does not reflect patellofemoral congruence at all ranges of motion of the patellofemoral joint. Second, although there are several landmarks to determine the femoral component rotation that can be used intraoperatively to ensure correct rotational alignment in TKA,[12,25,26] debate still remains. Olcott and Scott[17] found that flexion space symmetry within 3º of that desired was created with 90% of cases using the transepicondylar axis, 83% using anterior-posterior axis of Whiteside, and 70% using a posterior condylar reference, showing that the posterior condylar line is

the least reliable landmark. Third, varus knees tend to have medial condylar wear.[21,23] If femoral component position is adjusted according to this posterior condylar line, the values would be relatively externally rotated. The value of 0º or 1º determined by the navigation system would actually be 3º to 4º of external rotation. This may be the reason for the absence of statistical significance in our results. Fourth, one of the drawbacks of the navigation system is the surgeon's factor because registration is dependent on the visually identified anatomic landmarks. This leads to errors in the initial mechanical axes and femoral component reference axes formulated by the navigation system. Finally, this study was based on small numbers. More patient cases and longer follow-up are needed to investigate whether the various degrees of external rotation (0º-6º) determined by the navigation system affects the patellofemoral congruency and whether the navigation system has a positive effect on determining optimal rotational alignment of the femoral component in TKA.

REFERENCES

1. Mochizuki RM, Schurman DJ. Patellar complications following total knee arthroplasty. J Bone Joint Surg Am. 1979;61:879-883.
2. Rhoads DD, Noble PC, Reuben JD, Mahoney OM, Tullos HS. The effect of femoral component position on patellar tracking after total knee arthroplasty. Clin Orthop Relat Res. 1990;(260):43-51.
3. Eisenhuth SA, Saleh KJ, Cui Q, Clark CR, Brown TE. Patellofemoral instability after total knee arthroplasty. Clin Orthop Relat Res. 2006;446:149-160.
4. Berger RA, Crossett LS, Jacobs JJ, Rubash HE. Malrotation causing patellofemoral complications after total knee arthroplasty. Clin Orthop Relat Res. 1998;(356):144-153.
5. Chauhan SK, Scott RG, Breidahl W, Beaver RJ. Computer-assisted knee arthroplasty versus a conventional jig-based technique. A randomised, prospective trial. J Bone Joint Surg Br. 2004;86:372-377.
6. Bathis H, Perlick L, Tingart M, Luring C, Zurakowski D, Grifka J. Alignment in total knee arthroplasty. A comparison of computer-assisted surgery with the conventional technique. J Bone Joint Surg Br. 2004; 86:682-687.
7. Luring C, Hufner T, Perlick L, Bathis H, Krettek C, Grifka J. Soft tissue management in knees with varus deformity. Computer-assisted sequential medial ligament release. Orthopade. 2005;34:1118, 1120-1122, 1124.
8. Clemens U, Miehlke RK. Experience using the latest OrthoPilot TKA software: a comparative study. Surg Technol Int. 2003;11:265-273.
9. Griffin FM, Insall JN, Scuderi GR. Accuracy of soft tissue balancing in total knee arthroplasty. J Arthroplasty. 2000;15:970-973.
10. Miller MC, Berger RA, Petrella AJ, Karmas A, Rubash HE. Optimizing femoral component rotation in total knee arthroplasty. Clin Orthop Relat Res. 2001:38-45.
11. Anouchi YS, Whiteside LA, Kaiser AD, Milliano MT. The effects of axial rotational alignment of the femoral component on knee stability and patellar tracking in total knee arthroplasty demonstrated on autopsy specimens. Clin Orthop Relat Res. 1993 Feb;(287):170-177.
12. Arima J, Whiteside LA, McCarthy DS, White SE. Femoral rotational alignment, based on the anteroposterior axis, in total knee arthroplasty in a valgus knee. A technical note. J Bone Joint Surg Am. 1995;77:1331-1334.
13. Akagi M, Matsusue Y, Mata T, et al. Effect of rotational alignment on patellar tracking in total knee arthroplasty. Clin Orthop Relat Res. 1999;(366):155-163.
14. Akagi M, Yamashita E, Nakagawa T, Asano T, Nakamura T. Relationship between frontal knee alignment and reference axes in the distal femur. Clin Orthop Relat Res. 2001;(388):147-156.
15. Barrack RL, Schrader T, Bertot AJ, Wolfe MW, Myers L. Component rotation and anterior knee pain after total knee arthroplasty. Clin Orthop Relat Res. 2001;(392):46-55.
16. Berger RA, Rubash HE, Seel MJ, Thompson WH, Crossett LS. Determining the rotational alignment of the femoral component in total knee arthroplasty using the epicondylar axis. Clin Orthop Relat Res. 1993;(286):40-47.
17. Olcott CW, Scott RD. A comparison of 4 intraoperative methods to determine femoral component rotation during total knee arthroplasty. J Arthroplasty. 2000;15:22-26.
18. Laskin RS. Flexion space configuration in total knee arthroplasty. J Arthroplasty. 1995; 10:657-660.
19. Hollister AM, Jatana S, Singh AK, Sullivan WW, Lupichuk AG. The axes of rotation of the knee. Clin Orthop Relat Res. 1993:259-268.
20. Churchill DL, Incavo SJ, Johnson CC, Beynnon BD. The transepicondylar axis approximates the optimal flexion axis of the knee. Clin Orthop Relat Res. 1998:111-118.
21. Griffin FM, Insall JN, Scuderi GR. The posterior condylar angle in osteoarthritic knees. J Arthroplasty. 1998;13:812-815.
22. Yoshino N, Takai S, Ohtsuki Y, Hirasawa Y. Computed tomography measurement of the surgical and clinical transepicondylar axis of the distal femur in osteoarthritic knees. J Arthroplasty. 2001;16:493-497.
23. Matsui Y, Kadoya Y, Uehara K, Kobayashi A, Takaoka K. Rotational deformity in varus osteoarthritis of the knee: analysis with computed tomography. Clin Orthop Relat Res. 2005;(433):147-151.
24. Jazrawi LM, Birdzell L, Kummer FJ, Di Cesare PE. The accuracy of computed tomography for determining femoral and tibial total knee arthroplasty component rotation. J Arthroplasty. 2000;15:761-766.
25. Olcott CW, Scott RD. The Ranawat Award. Femoral component rotation during total knee arthroplasty. Clin Orthop Relat Res. 1999;(367):39-42.
26. Fehring TK. Rotational malalignment of the femoral component in total knee arthroplasty. Clin Orthop Relat Res. 2000;(380):72-79.

Validation of Computer-assisted Open-wedge High Tibial Osteotomy Using Three-dimensional Navigation

YUJI YAMAMOTO, MD; YASUYUKI ISHIBASHI, MD; EIICHI TSUDA, MD; HAREHIKO TSUKADA, MD; YUKA KIMURA, MD; SATOSHI TOH, MD

abstract

An unintended increase in the posterior tibial slope after open-wedge high tibial osteotomy (HTO) can influence knee kinematics and stability. The objective for this study was to validate the change of the tibial slope obtained from three-dimensional (3D) navigation in open-wedge HTO by comparing it with that evaluated with computed tomography. Human cadaver knees were used. The open-wedge HTO was performed to maintain the anatomic tibial slope according to the navigation system. 3D navigation could provide surgeons with reliable information not only to determine appropriate coronal alignment but also to maintain the anatomic tibial slope in open-wedge HTO.

High tibial osteotomy (HTO) is an established operative procedure for correction of varus deformity in patients with unicompartmental osteoarthritis.[1,2] Medial open-wedge HTO with interposition of bone grafts or hydroxyapatite wedges has been reported.[3,4] It has become popular recently because it does not introduce peroneal nerve problems, as well as the simplicity of the procedure, shorter surgical time, more precise correction, enhancement of bone stock, and avoidance of changes in the proximal morphologic characteristics of the tibia.[3,5,6] In addition, concomitant anterior cruciate ligament (ACL) reconstruction may be easier with the medial open-wedge osteotomy than with the lateral closed-wedge osteotomy.[7] However, studies have shown that the posterior tibial slope of the proximal tibia tends to increase when performing a medial open-wedge HTO.[5,8] Furthermore, an unintended increase in posterior tibial slope can influence knee kinematics, stability,[9] and tibiofemoral contact pressure10 and potentially cause knee pain and loss of normal knee extension.[11] Therefore, in open-wedge HTO, both coronal alignment and sagittal alignment should be given close attention. Three-dimensional (3D) navigation is available for open-wedge HTO and can monitor simultaneously both the coronal and sagittal alignment, such as the change in the posterior tibial slope.

The objective of this study was to validate the change of the tibial slope obtained from 3D navigation in open-wedge HTO by comparing it with that evaluated with computed tomography (CT). In addition, the open-wedge angle along the anteromedial tibial cortex and the length of the anterior and posterior opening gaps of the open-wedge HTO, which maintain the anatomic tibial slope with 3D navigation, were measured with postoperative CT.

MATERIALS AND METHODS

Specimen Preparation

Six fresh frozen human cadaver knees (62.5 ± 11.4 years; range, 50 – 82 years) were used in this study. The femur and tibia were cut approximately 20 cm from the joint line, and all soft tissue except ligaments, menisci, and joint capsule was removed. A preoperative 3D image was obtained in all specimens using a 16-detector CT scanner (Light Speed Ultra 16, GE Healthcare, Milwaukee, Wisconsin). The cadaveric knee was then connected with a skeleton model that included the pelvic, hip, and ankle joints by using an orthodontic resin so that navigation-assisted open-wedge HTO was simulated.

Drs Yamamoto, Ishibashi, Tsuda, Tsukada, Kimura, and Toh are from the department of Orthopaedic Surgery, Hirosaki University Graduate School of Medicine, Hirosaki, Aomori, Japan.

Orthopedics was unable to determine whether Drs Yamamoto, Ishibashi, Tsuda, Tsukada, Kimura, or Toh have any relevant financial relationships to disclose or whether they are paid consultants for any companies.

Correspondence should be addressed to: Yuji Yamamoto, MD, Department of Orthopaedic Surgery, Hirosaki University Graduate School of Medicine, 5 Zaifu-cho, Hirosaki, Aomori, 036-8562, Japan.



Figure 1: Experimental set up of the navigation-assisted open-wedge high tibial osteotomy.

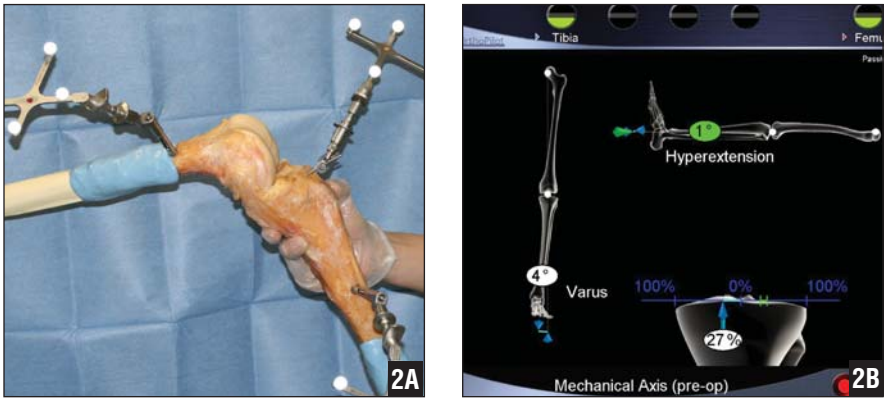

Figure 2: A, Human cadaver knee with transmitters. B, Screen shot of the preoperative leg alignment.

Procedures of Open-wedge High Tibial Osteotomy Using 3D Navigation

A kinematics-based image-free navigation system (OrthoPilot; B. Braun Aesculap, Tuttlingen, Germany) with HTO software version 1.4 (3D Open-wedge; B. Braun Aesculap) was used for all experiments (Figure 1). The transmitter was fixed on the distal femur and the distal tibia (tibial shaft) with a bicortical screw. To determine the mechanical leg axis, kinematic data including hip, ankle, and knee joints were registered. Anatomic landmarks, such as the medial epicondyle, lateral epicondyle, medial malleolus, lateral malleolus, central point of the ankle, and medial point of the tibial plateau were registered with a pointer. For 3D HTO navigation, an additional transmitter was fixed on the tibia part proximal from the cutting site with 2.5-mm k-wire (Figure 2) so that the distal and proximal tibia portions could be navigated directly against each other. The initial position of the proximal tibia was also registered. Once the registration was done, the mechanical leg axis was visualized continuously. The osteotomy began approximately 3 cm distal to the medial joint line at the medial cortex of the proximal tibia and was just proximal to the tibial tubercle, leaving 5- to 10 mm of the lateral tibial cortex intact. With monitoring of the mechanical leg axis and change of the tibial slope provided by navigation, the osteotomy was stabilized using a plate (POSITION HTO Plate; B. Braun Aesculap) with a 7-mm rectangular spacer block, maintaining the anatomic tibial slope (Figure 3). The plate was placed at the center of the medial cortex of the proximal tibia.

Evaluation of Tibial Slope, Open-wedge Angle, and Anterior and Posterior Opening Gaps

The correction angle in the coronal plane and change of the tibial slope were determined in the preoperative and postoperative 3D-CT (Figure 4). The data obtained from CT was compared with those obtained from the navigation system. In addition, the open-wedge angle along the anteromedial tibial cortex and the length of the anterior and posterior opening gaps was measured in the postoperative 3D-CT (Figure 5). The anatomic points for measuring the opening gaps were determined using the methods described by Song et al.[16] The point for the anterior opening gap was the anteromedial cortex of the proximal tibia (posteromedial aspect of tibial tuberosity only) on the lines of the osteotomy. Meanwhile, the point for the posterior opening gap was the posteromedial cortex of the proximal tibia on the lines of the osteotomy. A Wilcoxon signed-rank test was used for statistical analysis (SPSS 16.0; SPSS Science Inc, Chicago, Illinois)

RESULTS

After open-wedge HTO, the femorotibial mechanical axis obtained from the navigation system was corrected from varus 2.3° ± 1.2° (range, varus 1° – 4°) to valgus 5.0° ± 2.8° (range, valgus 2°– 8°). Therefore, the change in the femorotibial mechanical axis was a mean valgus of 7.3° ± 1.6° (range, 5°– 9°). Meanwhile, the change in femorotibial angle on the coronal plane on CT was a mean valgus of 6.8° ± 1.1° (range, 6°– 8°). There was no statistically significant difference between the correction angle of the coronal plane in navigation and CT data ($P > .05$).

With regard to the posterior tibial slope, data obtained from navigation and CT are presented in Table 1. Because the osteotomy was fixed to maintain the anatomic tibial slope with a viewing navigation monitor, the increase of the posterior tibial slope on the navigation system was only 0.2° ± 0.4° (range, 0°– 1°) (Table 1). Based on CT measurement, the posterior tibial slope was maintained, measuring 10.1° ± 1.7° preoperatively and 10.6° ± 2.2° postoperatively. There was no statistically significant difference in change in posterior tibial slope between the navigation and CT data ($P > .05$).

The length of the anterior and posterior opening gaps, and the open-wedge angle along the anteromedial tibial cortex, are presented in Table 2. The anterior opening gap was 61% (range, 53% – 69%) of the posterior opening gap, and the open-wedge angle was 4.6° ± 0.4° (range, 4.0°–5.1°) when the anatomic tibial slope was preserved using 3D navigation.

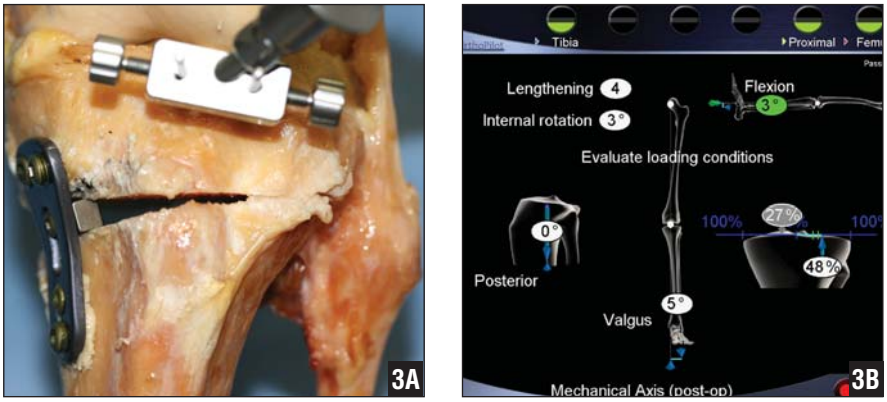

Figure 3: A, Human cadaver knee after open-wedge high tibial osteotomy. B, Screen shot of the postoperative leg alignment and the change in the tibial slope.

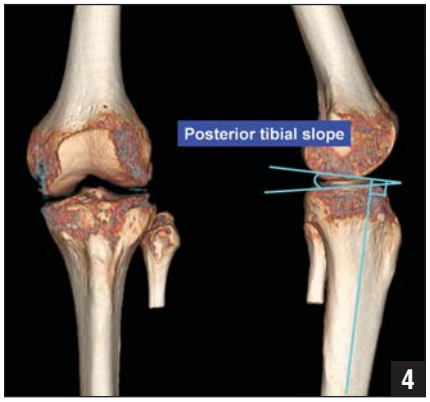

Figure 4: Measurement of the posterior tibial slope on 3D-CT.

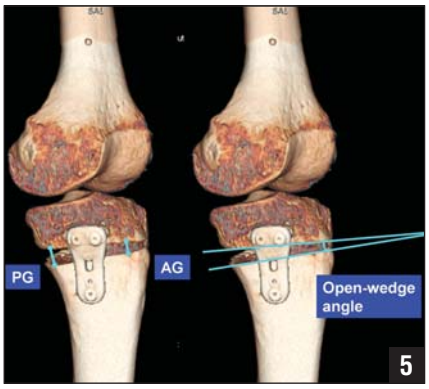

Figure 5: Measurement of the anterior and posterior opening gaps and open-wedge angle on postoperative 3D-CT.

Discussion

In this study, the changes of the tibial slope on 3D navigation after open-wedge HTO were compared with those on CT. In addition, the open-wedge angle along the anteromedial tibial cortex and the length of the anterior and posterior opening gaps in the open-wedge HTO that preserve the anatomic tibial slope were determined on postoperative CT.

Although HTO for patients with unicompartmental osteoarthritis is performed to correct varus deformity in the coronal plane, open-wedge HTO tends to increase posterior tibial slope in the sagittal plane simultaneously. An undesired increase in the posterior tibial slope can limit full extension of the knee joint and cause anterior knee pain. Watanabe et al[11] reported a revision HTO correcting sagittal alignment with a dynamic external ring fixator to treat anterior knee pain and a fixed flexional deformity associated with a previous failed medial open-wedge HTO.

An unintended increase in tibial slope also leads to excessive anterior translation and subluxation in patients with ACL deficiency.[12] Giffin et al[9] evaluated the effects of altering tibial slope on the biomechanics of the knee. They observed that increasing the slope causes an anterior shift in tibial resting position, which is accentuated under axial loads. This finding suggests that increasing the tibial slope may be beneficial in reducing tibial sag in a PCL-deficient knee, whereas decreasing the slope may be protective in an ACL-deficient knee. Therefore, during open-wedge HTO, both coronal alignment and sagittal leg alignment should be monitored.

A navigation system has been used successfully in open-wedge HTO, with the advantage of continuous real-time visualization of the limb alignment.[13-16] However, previous navigation systems could only monitor coronal leg alignment. The new version 3D navigation systems are available for open-wedge HTO and can provide intraoperative real-time alignment not only of the coronal plane but also of the sagittal plane, such as the change in the posterior slope.

Noyes et al[17] reported 3D analysis of the proximal tibia to show how the angle of the opening wedge along the anteromedial tibial cortex influences the tibial slope (sagittal plane) and valgus correction (coronal plane) during medial open-wedge osteotomy. They determined that the anterior osteotomy gap at the tibial tubercle must be half the posteromedial gap to maintain the normal sagittal tibial slope. Every millimeter of gap error at the tibial tubercle resulted in approximately 2° of change in the tibial slope. Their specific measurements and calculations provide the surgeon with the ability to determine the appropriate anteromedial tibial opening wedge to maintain or correct the tibial slope and to obtain the desired coronal axial alignment. Song et al[16] examined methods for avoiding unintended increases in posterior tibial slope in open-wedge HTO using computer-simulated 3D virtual surgery. The virtual surgery demonstrated that the anterior opening gap should be 67% of the posterior opening gap to preserve the original posterior slope. In addition, they performed navigated open-wedge HTO with two different plate sizes to maintain an anterior opening gap of approximately 67% of the posterior opening gap. Only a slight increase (0.4°) was observed in the posterior tibial slope after open-wedge HTO.

This study showed that the anatomic tibial slope could be maintained after open-wedge HTO with intraoperative monitoring of the change in the tibial slope using 3D navigation. The anterior opening gap was 61% of the posterior opening gap and open-wedge angle

Table 1

Posterior Tibial Slope in Medial Open-wedge High Tibial Osteotomy

	Navigation Data	Computed Tomography Data		
Specimen	Increase	Increase	Preoperative	Postoperative
1	0°	0.5°	9.4°	9.9°
2	0°	0.4°	11.1°	11.6°
3	0°	-0.2°	7.5°	7.3°
4	1°	0.1°	11.8°	11.9°
5	0°	1.8°	11.6°	13.4°
6	0°	0.3°	9.3°	9.6°
Mean ± SD	0.2° ± 0.4°[a]	0.5° ± 0.7°	10.1° ± 1.7°	10.6° ± 2.2°

[a] *P > .05 compared with the increase of the posterior tibial slope on CT.*

Table 2

Posterior Tibial Slope in Medial Open-wedge HTO

	Length of the Opening Gaps			
Specimen	AG (mm)	PG (mm)	A/P ratio	Open-wedge Angle (°)
1	5.7	10.7	0.53	5.1
2	5.8	9.4	0.62	4.6
3	4.3	7.3	0.59	4.8
4	6.0	8.7	0.69	4.0
5	5.4	8.7	0.62	4.3
6	5.6	9.3	0.60	4.9
Mean ± SD	5.5 ± 0.6	9.0 ± 1.1	0.61 ± 0.1	4.6 ± 0.4

Abbreviations: AG, anterior opening gap; A/P, anterior/posterior; PG, posterior opening gap

was 4.6° when the anatomic tibial slope was preserved using 3D navigation. A plate with a wedge-shaped spacer block in place of a rectangular spacer block may be suitable for stabilizing the osteotomy while preserving the anatomic tibial slope in open-wedge HTO. Results suggested that 3D navigation could provide surgeons with reliable information to maintain the anatomic tibial slope in open-wedge HTO.

REFERENCES

1. Bauer GC, Insall J, Koshino T. Tibial osteotomy in gonarthrosis (osteo-arthritis of the knee). *J Bone Joint Surg Am*. 1969; 51:1545-63.
2. Coventry MB, Ilstrup DM, Wallrichs SL. Proximal tibial osteotomy. A critical long-term study of eighty-seven cases. *J Bone Joint Surg Am*. 1993; 75:196-201.
3. Hernigou P, Medevielle D, Debeyre J, Goutallier D. Proximal tibial osteotomy for osteoarthritis with varus deformity. A ten to thirteen-year follow-up study. *J Bone Joint Surg Am*. 1987; 69:332-54.
4. Koshino T, Murase T, Saito T. Medial opening-wedge high tibial osteotomy with use of porous hydroxyapatite to treat medial compartment osteoarthritis of the knee. *J Bone Joint Surg Am*. 2003; 85-A:78-85.
5. Marti CB, Gautier E, Wachtl SW, Jakob RP. Accuracy of frontal and sagittal plane correction in open-wedge high tibial osteotomy. *Arthroscopy*. 2004; 20:366-72.
6. Hernigou P,Ma W. Open wedge tibial osteotomy with acrylic bone cement as bone substitute. *Knee*. 2001; 8:103-10.
7. Dejour H, Neyret P, Boileau P, Donell ST. Anterior cruciate reconstruction combined with valgus tibial osteotomy. *Clin Orthop Relat Res*. 1994:220-228.
8. Hohmann E, Bryant A, Imhoff AB. The effect of closed wedge high tibial osteotomy on tibial slope: a radiographic study. *Knee Surg Sports Traumatol Arthrosc*. 2006; 14:454-459.
9. Giffin JR, Vogrin TM, Zantop T, Woo SL, Harner CD. Effects of increasing tibial slope on the biomechanics of the knee. *Am J Sports Med*. 2004; 32:376-82.
10. Rodner CM, Adams DJ, Diaz-Doran V, Tate JP, Santangelo SA, Mazzocca AD, Arciero RA. Medial opening wedge tibial osteotomy and the sagittal plane: the effect of increasing tibial slope on tibiofemoral contact pressure. *Am J Sports Med*. 2006; 34:1431-41.
11. Watanabe K, Tsuchiya H, Matsubara H, Kitano S, Tomita K. Revision high tibial osteotomy with the Taylor spatial frame for failed opening-wedge high tibial osteotomy. *J Orthop Sci*. 2008; 13:145-9.
12. Dejour H,Bonnin M. Tibial translation after anterior cruciate ligament rupture. Two radiological tests compared. *J Bone Joint Surg Br*. 1994; 76:745-9.
13. Hankemeier S, Hufner T, Wang G, Kendoff D, Zeichen J, Zheng G, Krettek C. Navigated open-wedge high tibial osteotomy: advantages and disadvantages compared to the conventional technique in a cadaver study. *Knee Surg Sports Traumatol Arthrosc*. 2006; 14:917-21.
14. Saragaglia D,Roberts J. Navigated osteotomies around the knee in 170 patients with osteoarthritis secondary to genu varum. *Orthopedics*. 2005; 28:s1269-74.
15. Maurer F,Wassmer G. High tibial osteotomy: does navigation improve results? Orthopedics. 2006; 29:S130-2.
16. Song EK, Seon JK, Park SJ. How to avoid unintended increase of posterior slope in navigation-assisted open-wedge high tibial osteotomy. *Orthopedics*. 2007; 30:S127-31.
17. Noyes FR, Goebel SX, West J. Opening wedge tibial osteotomy: the 3-triangle method to correct axial alignment and tibial slope. *Am J Sports Med*. 2005; 33:378-87.

Real-time Computer-assisted Notch Assessment in Anterior Cruciate Ligament Repair

BRUNO E. GERBER, MD; M. BHATTACHARYYA, MD

abstract

Graft impingement can cause graft failure or movement restrictions. Intraoperative computer-assisted referencing of the tibial and femoral geometry, including precise mapping of the intercondylar notch, allows placement of the tunnels by real-time calculation balancing the impingement risks vs isometry. Biological fixation with bone cylinders locks the graft flush with the joint line and requires more accurate tunnel placement to avoid graft impingement. In 45 patients who underwent such navigation controlled tunnel placement 41 had no need for notchplasty. In two cases, the notchplasty was performed immediately for obvious osteophyte restriction. A notchplasty was added two times after the first referencing to obtain satisfactory isometry. At staged follow up to 18 months, we found no laxity, flexion contracture with a mean flexion arc over 130°, or tunnel widening. With computer-navigated real-time assessment of notch geometry, full functional recovery and stability were obtained, and unnecessary notchplasties were avoided even with a less flexible biological graft fixation.

Graft impingement can cause graft elongation and failure (Figure 1) or movement restrictions through the growth of a cyclops lesion, or localized anterior fibrosis that limits extension.[1] As long as the intact anterior cruciate ligament (ACL) occupies the notch, no significant osteophytic growth is observed. Further, with the near to isometric position of the bundles, the ligament is neither overstretched nor impinged.[2] To avoid these risks to the graft in ACL repair, many surgeons increase the size of the intercondylar notch routinely.[3] This allows for greater isometry, especially when the graft fixation is away from the joint line. Such notchplasties, however, produce additional intra-articular bleeding[4] with risks for the cartilage and for arthrofibrosis. Notchplasty performed with a radiofrequency device reduces hemarthrosis[5] but impairs the vitality of the bone around the tunnel entries where the ingrowth of the graft is most important. Sound criteria to identify cases that really require notchplasty and to avoid unnecessary procedures are therefore indispensable.

Intraoperative computer-assisted referencing of the tibial and femoral functional geometry, including precise mapping of the intercondylar notch, allows real-time calculated balancing of the impingement risks vs isometry for anatomical placement of the tibial tunnel in relation to an optimized femoral tunnel entry. Overstretching and lifting off the graft are avoided,[6] and the biological graft fixation can fix the graft flush tightly with the joint line (Figure 2). This provides better stability, without undue stress on the graft, as well as prevents widening of the tunnel.

MATERIALS AND METHODS

Between 2004 and 2005, 45 patients (mean age, 31.2 years) underwent navigation-controlled tunnel placement using an image-free computer-assisted surgical navigation system (OrthoPilot; B. Braun Aesculap, Tuttlingen, Germany). After mounting passive reflective rigid references bodies onto the tibial shaft and the medial distal femur, the biomechanical axes and preoperative instability are recorded. The width of the harvested graft is measured. Then the tibial plateau with its landmark is referenced, followed by precise mapping of

Drs Gerber and Bhattacharyya are from the University Hospital Lewisham, London SE13 6LH, United Kingdom.

Drs Gerber and Bhattacharyya have no relevant financial relationships to disclose.

Correspondence should be addressed to: Bruno E. Gerber, MD, Orthopaedic Department, University Hospital Lewisham, London SE13 6LH, United Kingdom.

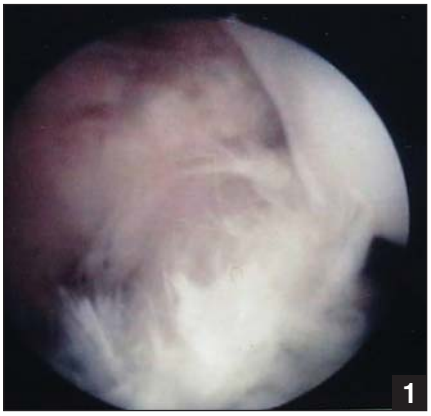

Figure 1: Secondary graft rupture due to anisometric tunnel position with impingement.

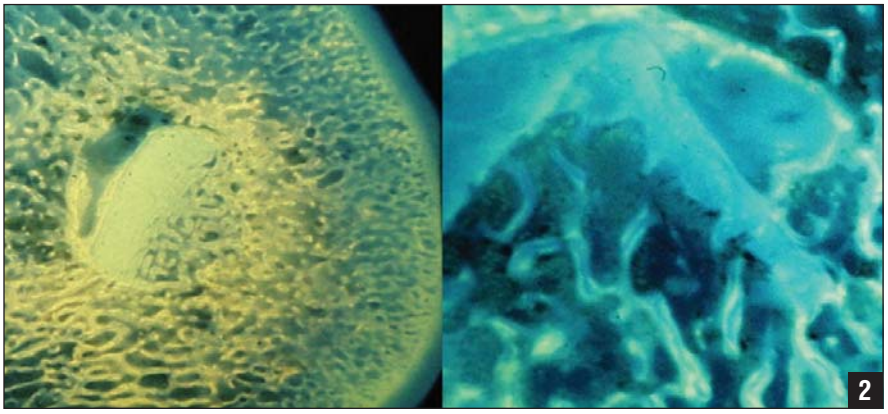

Figure 2: Biological fixation with bony ingrowth of the graft in the femoral and tibial tunnel entry area (own experimental animal study).

the notch entry and the lateral notch wall in the area of the natural femoral attachments of the anterior cruciate ligament (ACL) (Figure 3) and by probing of the medial and lateral notch walls as well as the central and lateral over-the-top position (Figure 4). With all these elements, the computer calculates the graft impingement risk vs isometry (Figure 5) and directs the navigated pointer toward the femoral tunnel entry point for impingement-free isometric graft positioning.

Criterion used to determine whether to perform a notchplasty was 1) the intercondylar notch of the ACL deficient knee was found walled up with a wide osteophyte or 2) no isometric impingement-free point could be found while navigating the femoral tunnel entry. In the latter case the notchplasty is performed followed by new referencing of the notch geometry and the isometry, and impingement risk is recalculated to guide the instrumented pointer toward the correct femoral tunnel entry point.

Accordingly, placed guidewires are overreamed by hollow cylindrical diamond reamers producing autologous bony locking bolts for biological graft fixation. Finally, the anteroposterior and rotational stability are reassessed with the navigation system and compared with the instrumented preoperative instability results.

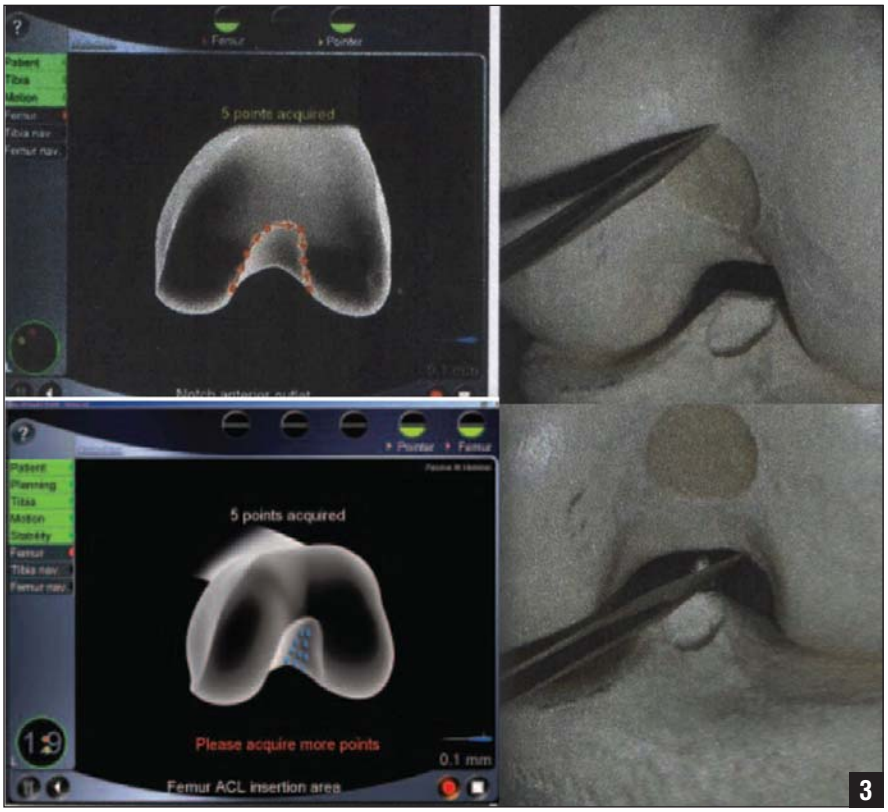

Figure 3: Computer-navigated notch assessment: logging of notch entry geometry; mapping of lateral notch wall.

All patients had continuous passive motion in the recovery room and were discharged between the first and the fourth postoperative day, including those with over 90° of flexion with a cricket splint in 10° to 15° of flexion and full weight bearing and those with less than 90° of flexion without any splinting but with partial weight bearing. Free full weight bearing was allowed after 6 weeks.

All patients were followed at 6 and 12 weeks and 6 to 9 months after surgery, then annually with x-rays.

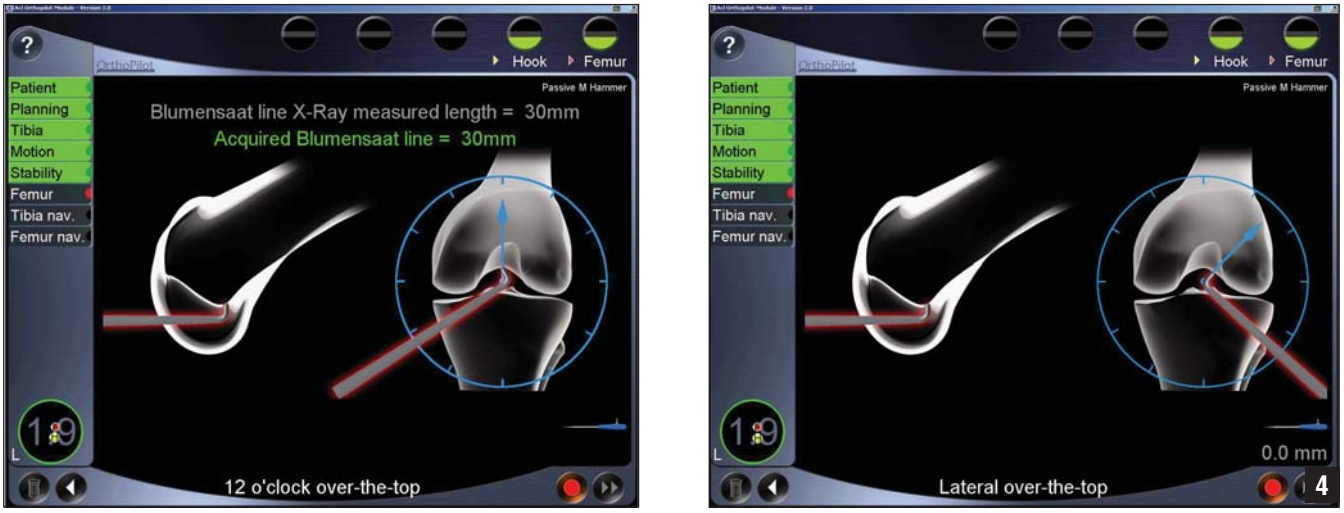

Figure 4: Locating central and lateral over-the-top position.

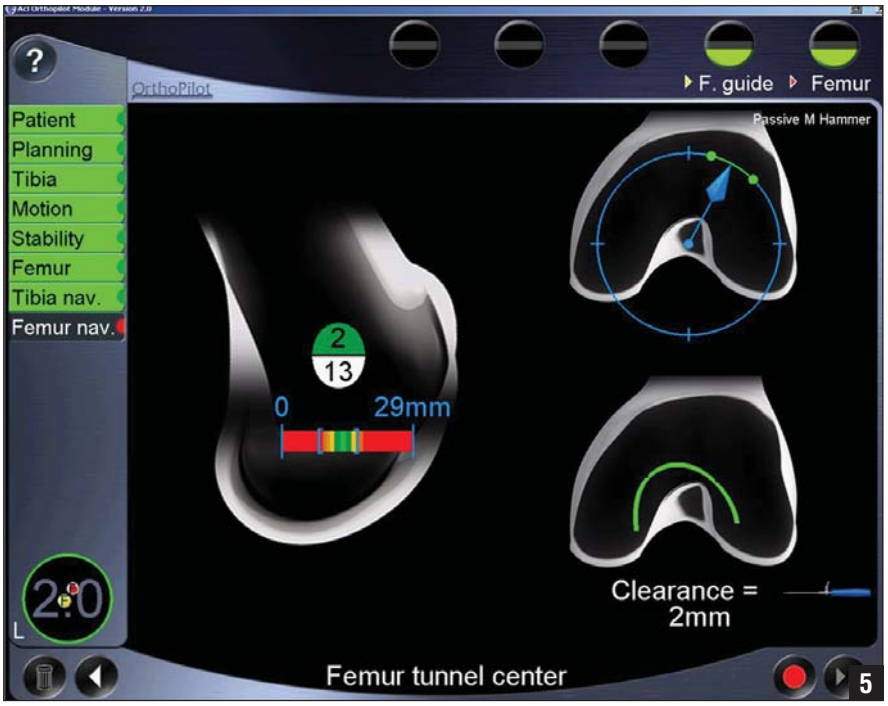

Figure 5: Calculation of isometry vs risk of graft impingement.

Results

Of the 45 patients studied, 41 did not undergo notchplasty. In two cases, notchplasty was performed immediately because of osteophyte restriction. In two other cases, notchplasty was added after the first referencing to obtain satisfactory isometry. At 18 months' follow up, no patients had laxity or flexion contracture. Mean flexion arc was 130°, and there was no tunnel widening.

Discussion

For optimal stability, ACL reconstruction should have the tunnel apertures at the anatomic attachment area of the genuine cruciate as well as a free intercondylar notch to achieve good overall isometry and range of motion. For anatomic tunnel placement, the primary issue is to place the joint entry of the guidewire where it is intended. This is especially important when using an arthroscope, which may have picture distortion. Experience brings about the knowledge which way to exceed the supposed anatomical position to be on the safe side but still leaves an amount of uncertainty.

With stiff ACL replacements such as artificial ligaments, this limitation in manually placing the tunnel entries precisely can lead to overstressing the implanted structure and graft failure. With autografts, in many cases, such overstressing and rupture of the graft are avoided with a graft that gives way to a certain extent (like hamstrings) and by a more flexible fixation at some distance from the joint entries. However, this produces a lift off of the graft at every cycle, makes the ingrowth of the graft into the host bone more difficult, and contributes to the risk of tunnel widening in addition to reduced stability.

For the graft tension and isometry, the primary problem is that it cannot be visualized before and only measured once at least a small tunnel has been

drilled. The influence of a graft deviation on the isometry and the risk of graft impingement, which lead to a reactive growth of a cyclops and restrictions of the range of movement, cannot be evaluated in advance without simulation.

To prevent impingement of the graft and rubbing over the ridge of the notch entry, a notchplasty is often performed routinely. This increases the incidence of postoperative hemarthrosis with the risk of arthrofibrosis. To prevent this complication by performing the notchplasty with radiofrequency devices jeopardizes the ingrowth of the graft or the replacement into the bony tunnel wall around the joint entry as the vitality in this area is reduced.

For both issues, computer-assisted navigation provides a solution through the real-time three dimensional assessment of the notch geometry. The tunnel entry placement is directed alongside the tibial spine area and the recorded lateral notch wall and is independent of any visualization or image distortion. Graft impingent and isometry are calculated with regard to the recorded notch entry and possible deviation of the graft around it before any drilling, and the guidewire is directed accordingly using an aiming device before insertion. Only when a wire tip position without graft impingement and with good isometry cannot be found, notchplasty is performed using the shaver with the acromionizer blade and the new notch geometry recorded to guide the a adjusted tunnel placement. Thus, all unnecessary notchplasties can be avoided

CONCLUSION

Computer-navigated assessment of notch geometry allows for the calculation of accurate tunnel placement, balancing the risk of impingement against isometry. Early intensive rehabilitation is possible, leading to full functional recovery and stability while avoiding graft impingement. If carried out only when needed to achieve good isometry without impingement, the percentage of required notchplasties falls below 10%, even with less flexible biological graft fixation.

REFERENCES

1. Bradley DM, Bergman AG, Dillingham MF. MR imaging of cyclops lesions. *AJR Am J Roentgenol*. 2000;174(3):719-726.
2. May DA, Snearly WN, Bents R, Jones R. MR imaging findings in anterior cruciate ligament reconstruction: evaluation of notchplasty. *AJR Am J Roentgenol*. 1997;169(1):217-222.
3. Kanamiya T, Hara M, Naito M. Magnetic resonance imaging evaluation after re-notchplasty at second-look arthroscopy. *Arthroscopy*. 2002;18(6):584-588.
4. Pape D, Seil R, Adam F, Gödde S, Georg T, Rupp S, Kohn D. Blood loss in anterior cruciate ligament (ACL) reconstruction with and without intercondylar notchplasty: does it affect the clinical outcome? *Arch Orthop Trauma Surg*. 2001;121(10):574-577.
5. Camillieri G, Margheritini F, Maresca G, Mariani PP. Postoperative bleeding following notchplasty in anterior cruciate ligament reconstruction: thermal radio frequency versus powered instrumentation. *Knee Surg Sports Traumatol Arthrosc*. 2001;9 (1):12-14.
6. Hame SL, Markolf KL, Hunter DM, Oakes DA, Zoric B. Effects of notchplasty and femoral tunnel position on excursion patterns of an anterior cruciate ligament graft. *Arthroscopy*. 2003;19 (4)340-345.

Accuracy of Navigation: A Comparative Study of Infrared Optical and Electromagnetic Navigation

EUN KYOO SONG, MD; JONG KEUN SEON, MD; SANG JIN PARK, MD; TAEK RIM YOON, MD

abstract

We evaluated the accuracy of navigation systems for measuring the mechanical axis in patients undergoing total knee arthroplasty and in the synthetic bone model. Infrared optical and electromagnetic navigation systems were compared. Both systems were found to be accurate and reproducible in an experimental environment. However, the accuracies of both systems were affected by erroneous registration, and the optical system was found to be more reproducible. In clinical situations, the mean difference was 1.23°, and difference greater than 3° occurred in 15% of clinical trials. These discordances may have been due to ambiguous anatomic landmarks causing registration errors and the possibility of electromagnetic signal interference in the operating room.

The accuracies of lower extremity alignment and implant position significantly influence long-term results of total knee arthroplasty (TKA). Recent advances in computer technology have improved navigation systems and reduced lower extremity alignment and implant positioning outliers compared with conventional alignment tools.[1-6] Computer-assisted navigation includes optical navigation and electromagnetic navigation systems and the ultrasound-guided navigation system introduced recently. Experimentally, all navigation systems are known to have errors of less than 1 mm or 1°.[2,7-11]

Of these different systems, the infrared optical navigation system has been well popularized, and clinical results accumulated over 10 years confirm its expected accuracies.[2,12-15] Although the accuracy of electromagnetic navigation remains controversial with regard to metallic interference, recently developed equipment is known to be more accurate and much less affected by intraoperative metallic instrumentation.[16,17]

Moreover, few comparative studies have been conducted on the accuracies of optical navigation and electromagnetic navigation systems. This study was undertaken to evaluate the accuracy of infrared optical and electromagnetic navigation systems under clinical and experimental conditions.

MATERIALS AND METHODS

In Vivo Experiment

We compared the preoperative lower extremity mechanical axis of 20 cases of TKA using the OrthoPilot optical navigation system (B. Braun Aesculap, Tuttlingen, Germany) and the AxiEM electromagnetic navigation system- (Medtronic Navigation, Coal Creek, Colorado). Preoperatively, mechanical axes using weight-bearing anteroposterior full leg radiography was taken.

For OrthoPilot navigation, transmitters were fixed to the distal femur and proximal tibia. Kinematic registration was done for the hip, knee, and ankle joint centers for a range of motion study. Anatomic landmarks such as the center of distal femur, proximal tibia, and ankle and both malleoli of the ankle were registered using probes, and mechanical axes were measured. For AxiEM navigation, trackers were fixed to femur and tibia. Only the hip center was registered using the kinematic method, and the other anatomic

Drs Song, Seon, Park, and Yoon are from the Center for Joint Disease, Chonnam National University Hwasun Hospital, Jeonnam, Korea.

Dr. Song discloses a relationship with the B. Braun Aesculap speakers bureau. Drs Seon and Park have no relevant financial relationships to disclose. ORTHOPEDICS *was unable to determine whether Dr. Yoon has any financial relationship to disclose or whether Dr. Yoon is a paid consultant for any companies.*

Correspondence should be addressed to: Sang Jin Park, MD, Center for Joint Disease, Chonnam National University Hwasun Hospital, 160 Ilsimri, Hwasuneup, Hwasungun, 519-809, Jeonnam, Korea.

Figure 1: Synthetic bone models. The hip, knee, and ankle joints are made of titanium, which has no effect on electromagnetic field. The knee joint is constrained to not allow varus or valgus motion.

landmarks were pointed and registered using a probe. Anatomic landmarks that can affect the mechanical axis include the center of distal femur and proximal tibia and both malleoli of the ankle. The order of application of both navigations was randomized, and single surgeon performed these clinical trials.

Comparison of Accuracies Using a Lower Extremity Synthetic Bone Model

To check the mechanical axis differences in an experimental model between the two navigation systems, we used a lower extremity bone model (Sawbones; Pacific Laboratories, Vashon, Washington), which extended from the pelvis to the foot. Mobile hip, knee, and ankle joints were made of titanium that was not affected by electromagnetic field. Varus or valgus motion was not allowed in the knee joint (Figure 1). Mechanical axes of synthetic bone were evaluated using the OrthoPilot the optical system and the AxiEM electromagnetic system. The registration process of both navigation systems was the same as a previously described process in an in vivo study. Four orthopedic surgeons participated in this experiment and applied both navigations 10 times independently. Two of the surgeons had performed more than 100 TKAs with navigation, whereas the other two had no such experience.

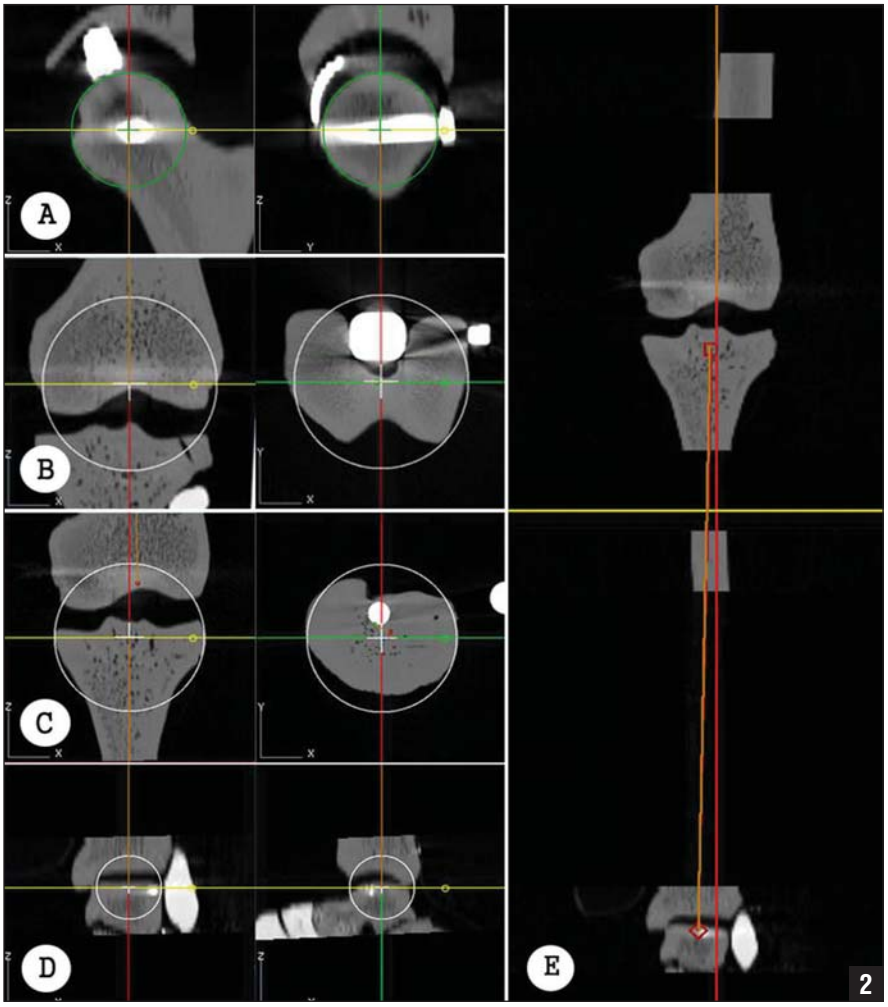

Figure 2: Orthodoc system. A, Femoral head center; B, center of distal femur; C, center of proximal tibia; D, ankle center; E, measurement of mechanical axis.

To obtain a true mechanical axis of the synthetic bone, the Orthodoc system (Robodoc preoperative total knee arthroplasty planning software; Curexo Technology Corporation, Sacramento, California) was used after obtaining helical computed tomography images (1.0-mm section thicknesses). We created 3D reconstruction images of saw bone and defined the center of the femur head, distal femur, proximal tibia, and ankle (Figure 2). The true mechanical axis was then obtained by computer after connecting the centers of the hip joint, distal femur, proximal tibia, and ankle. Two orthopedic surgeons checked it 5 times each.

Intentionally Erroneous Identification of Anatomic Landmarks

Using the same bone model, anatomic landmarks were intentionally erroneously identified and changes in the mechanical axis were recorded by both navigation systems (Figure 3). Centers of the distal femur, proximal tibia, ankle, and both medial and lateral malleoli centers were registered 10 mm medially and laterally compared with the original points, and the mechanical axis with original and erroneous data were compared. This process was performed by one operator.

Statistical Analysis

The Mann-Whitney test was used



Figure 3: Erroneous identification of anatomic landmarks. A, Distal femur; B, proximal tibia; C, ankle.

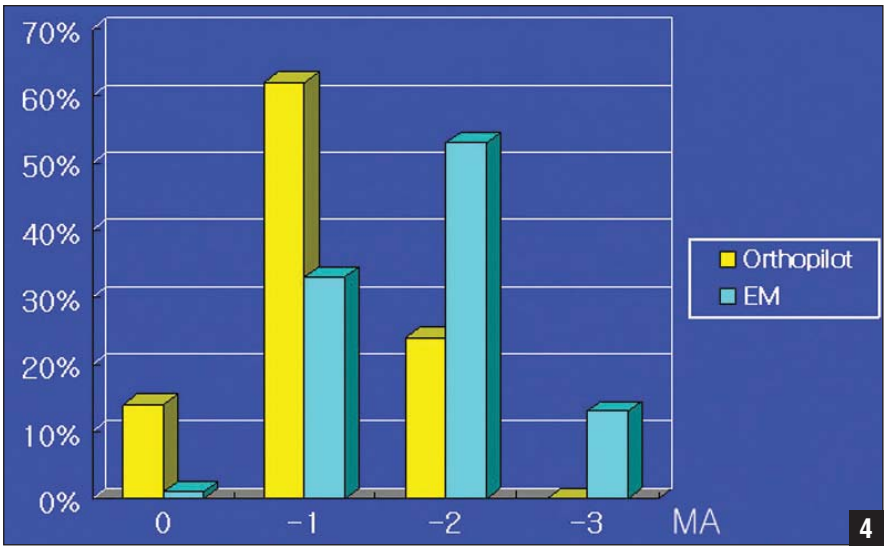

Figure 4: Results of mechanical axis evaluation using the OrthoPilot and AxiEM navigation systems. OrthoPilot showed varus values of 0º, 1º, 2° for the entire experimental trial, whereas AxiEM showed varus values of 0º, 1º, 2º, 3°.

to analyze anatomic axis differences, and Pearson's correlation analysis was used to analyze interobserver and intraobserver variances. SPSS version 12.0 Win (SPSS, Inc, Chicago, Illinois) was used throughout.

Results

Clinical Results

The mechanical axis was varus 9.45º ± 7.9° using weight-bearing anteroposterior radiographs, varus 9.02º ± 5.18° using the OrthoPilot navigation system, and varus 10.25° ± 5.10° using the AxiEM navigation system. AxiEM showed 1.23° more mean varus, but it had no statistical significance (P = .078). A difference greater than 3° occurred in 15% of cases (Table 1).

Experimental Results

The true mechanical axis of the synthetic bone was varus 1.25° by Orthodoc. OrthoPilot displayed varus 1.10° ± 0.64° change, and AxiEM displayed varus 1.78° ± 0.89° change. No mechanical axis differences were observed between the two navigations (P = .124) (Table 2). AxiEM provided greater varus than OrthoPilot. The mean difference was 0.68°.

OrthoPilot showed varus values of 0°, 1°, and 2° for the entire trial, whereas AxiEM showed varus values of 0º, 1º, 2°, and 3° for the entire trial. In 86% of trials, both navigation systems showed varus 1° or 2° of mechanical axis, which demonstrated relatively high accuracy and reproducibility of both navigation systems (Figure 4). No significant interobserver or intraobserver variance was detected. Pearson's correlation coefficient ranged from 0.611 to 0.791 for interobserver variance and from 0.798 to 0.934 for intraobserver variance ($P < .05$).

Change of Mechanical Axis After the Erroneous Identification of Anatomic Landmarks

With OrthoPilot, 0.2° valgus or varus changes of the mechanical axis were observed with 10-mm medial or later side erroneous registration of the center of the distal femur (Table 3). However, AxiEM showed a 1.76° valgus or 1.62° varus change in the same study. For the erroneous 10-mm medial or lateral registration from the center of the proximal tibia, OrthoPilot showed 1.24° valgus or 1.43° varus change, whereas AxiEM showed 1.69° valgus or 1.72° varus change.

When a 10-mm medial or lateral side of the medial or lateral malleoli registration occurred, OrthoPilot showed 0.33° varus or 0.33° valgus change, and AxiEM showed 1° varus or 1° valgus change. On the other hand, for incorrect registration of the ankle center, OrthoPilot was significantly affected and had 1.69° varus or 1.62° valgus changes. AxiEM

had no ankle center registration process.

OrthoPilot showed less aberration than AxiEM after intentionally erroneously identifying 10-mm medial and lateral side registrations from the center of the distal femur, proximal tibia, or bilateral ankle malleoli.

DISCUSSION

Computer navigation has become an important technology, and in many reports navigation has reduced mechanical axis outliers after TKA.[1-5,12,13] Of the available navigation systems, infrared optical navigation has become widely used, and recently electromagnetic and ultrasound navigated systems were introduced.[7-9,18]

Stiehl et al[16] compared the accuracies of optical and electromagnetic navigation systems using a cadaver in a standard operating room, and the investigators reported that precision was satisfactory for both optical and electromagnetic tracking for mechanical axis assessment. However, outliers were identified with electromagnetic tracking, causing concern that accuracy could be affected by electromagnetic forces in the operating room. Until now, few studies have clinically compared the accuracies of these two navigation systems. We wanted to determine whether the new electromagnetic navigation system could measure mechanical axes as precisely as an optical navigation system under standard operating conditions.

In patients undergoing TKA, one operator measured preoperative mechanical axes using the two different navigation systems. The mechanical axis measured using two navigation systems was found to be different, although there was no statistical significance. The mean difference was 1.23°, and electromagnetic navigation showed more varus in the same patients. In 85% of patients, the mechanical axis differences measured using two navigation systems were within 2°, but differences of more than 3° were recorded in 15%.

Table 1

Preoperative Mechanical Axes of TKA Patients[a]

	Scanogram	OrthoPilot	AxiEM
MA(°) varus	9.45 ± 7.9	9.02 ± 5.18	10.25 ± 5.10

Abbreviation: MA, Mechanical axes.
[a] (P = .078)

Table 2

Mechanical Axis of the Synthetic Bone Model[a]

	ORTHODOC(°)	OrthoPilot(°)	AxiEM(°)
A	-1.3 ± 0.14	-1.4 ± 0.54	-1.9 ± 0.68
B	-1.2 ± 0.16	-1.2 ± 0.47	-1.8 ± 0.64
C	[b]	-0.8 ± 0.83	-1.6 ± 0.86
D	[b]	-1.0 ± 0.54	-1.8 ± 0.83
Mean (SD)	-1.25 ± 0.15	-1.10 ± 0.64	-1.78 ± 0.79

[a]- Indicates mechanical varus; [b]It was not checked

These differences may be attributable to ambiguous anatomy with soft tissue coverage, which causes registration error, knee joint laxity with arthrotomy, and possible data outliers that result from signal interference by metallic surgical instrument and electrical devices in the operation room.

Yau et al[19] investigated the intra-observer errors in obtaining visually selected anatomic landmarks that were used in the registration process and concluded that the maximum error in mechanical axis was 1.32° in the coronal plane and 4.17° in the sagittal plane in a cadaver study. In this study, the mechanical axis was measured only one time by both navigations. Thus, we cannot evaluate the intraobserver variation. However, some variation can be expected even in the same patients because of soft tissue coverage of anatomic landmarks.

The optical navigation system used in this study had been employed clinically for more than 9 years. Although the electromagnetic navigation system is increasingly implemented and has several advantages such as a small tracker that can be fixed on a surgical incision site with minimal trauma, it has no line of sight capability. The system also presents problems with interaction with ferromagnetic instruments or other electrical equipment in operation room.

Experimentally, the accuracies of optical and electromagnetic navigation systems are known to be within 1 mm or 1°.[1,9,17-21] For the accuracy of infrared optical navigation systems, Pitto et al[1] reported that the mean error of the system was within 0.5° in the setting of normal alignment and within 1.0° in the setting of abnormal plane alignment. Many reports have been published on electromagnetic navigation systems.[9,17,18,20] Hummel et al[17] reported relatively accurate results for the Aurora electromagnetic system (Northern Digital Inc, Bakersfield, Calif) and found that the relative positional error was 0.97 mm and that its rotational error was 0.2-0.91°. However, it was also found that significant distortion can occur by interaction with metal (most significantly by 400 series stainless steel). Electromagnetic interference in the

Table 3

Changes in Mechanical Axis Due to the Erroneous Identifications of Anatomical Landmarks

Erroneous	MA Changes (°) OrthoPilot	AxiEM
Medial 10mm to CDF	0.20	1.76
Lateral 10mm to CDF	-0.20	-1.62
Medial 10mm to CPT	1.24	1.69
Lateral 10mm to CPT	-1.43	-1.72
Medial 10mm to MM	-0.33	-1.0
Lateral 10mm to LM	0.33	1.0
Medial 10mm to AC	-1.69	*
Lateral 10mm to AC	1.62	*

*Abbreviations: AC, ankle center; CDF, Center of Distal Femur; CPT, Center of Proximal Tibia; LM, Lateral Malleolar; MA, mechanical axis; MM, Medial Malleolar, ; - , Indication of varus change; *, It was not checked.*

operating field had lead to newly developed electromagnetic systems that improved accuracy. Schicho et al[21] studied the effect of metal instruments on the Aurora electromagnetic navigation system, which caused a mean 1.44-mm distance error when a Langenbeck hook was applied, a mean 0.53-mm distance error when a drill was applied, and a mean 2.37-mm distance error when an ultrasound scan head was applied. In addition, they reported findings for identical experiments using the Treo-EM system, and found a mean 0.21-mm distance error for a Langenbeck hook, 0.23-mm distance error for a drill, and 0.56-mm distance error for an ultrasound scan head.

In this trial, we experienced some discordance between the two systems for measuring the mechanical axis and thus investigated the accuracy of both systems under experimental conditions. To eliminate the interference of metal, the hip, knee, and ankle joints of the synthetic saw bone were made of titanium, which has no effect on an electromagnetic system. Further, the knee joint was constrained to not allow varus or valgus motion for precise measurement of mechanical axis of the synthetic bone model.

As a result, the true mechanical axis of bone model was varus 1.25° for the Orthodoc system, varus 1.1° for the OrthoPilot system, and varus 1.78° for the AxiEM system, which is not significantly different, indicating that both navigation systems are accurate. No intraobserver and interobserver differences were found, which meant both systems had high reproducibility. Further, relatively obvious anatomic structures of the bone model are thought to contribute to high reproducibility of both systems by reducing registration errors compared with some variability in an in vivo study with ambiguous anatomic landmarks. Even though in terms of numerical values, the mean difference between the two navigation system was 0.68°, which does not seem to be a significant difference in measuring the mechanical axis of the bone model. OrthoPilot showed 0°, varus 1°, and varus 2°, whereas AxiEM showed 0°, varus 1°, varus 2°, and varus 3°, indicating that OrthoPilot has better reproducibility with less variability. This study revealed that under the least favorable conditions, the two navigation systems could show a difference of 3° (for example, OrthoPilot 0° and AxiEM varus 3°). Furthermore, experimentally AxiEM yielded higher varus values, which could affect postoperative mechanical axis correction leading to valgus over correction, clinically.

When anatomic registration was incorrect (10-mm registration error study), mechanical axis measurements were affected in both navigation systems. AxiEM was affected more in every step (range, 1.0° to 1.76°). OrthoPilot was less affected (range, 0.2° to 1.69°), but it also had a significant change in mechanical axis measurement especially when proximal tibia and ankle centers were registered inadequately. Surgeons should therefore collect precise anatomic landmarks during the registration process to reduce potential errors in using navigation system.

Conclusion

In this study, infrared optical navigation and electromagnetic navigation systems were found to be accurate and reproducible in an experimental environment. However, the accuracies of both systems were affected by erroneous registration, and the levels of inaccuracy encountered were high for the electromagnetic system. Under clinical conditions, discordances between the two navigation systems were observed and may have been attributable to ambiguous anatomic points that cause registration errors and the possibility of electromagnetic signal interference in the operating environment.

References

1. Pitto RP, Graydon AJ, Bradley L, et al. Accuracy of computer-assisted navigation system for total knee replacement. *J Bone Joint Surg Br*. 2006;88:601-605.
2. Stulberg SD, Loan P, Sarin V. Computer-assisted navigation in total knee replacement results of an initial experience of thirty five patients. *J Bone Joint Surg Am*. 2002;84:90-98.
3. Macule-Beneyto F, Hernandez-Vaquero D, Segur-Vilalta JM, et al. Navigation in total knee arthroplasty. A multicenter study. *Int Orthop*. 2006;30:536-540.
4. Saragaglia D, Picard F, Chaussard C, et al. Computer-assisted knee arthroplasty: com-

parison with a conventional procedure. Results of 50 cases in a prospective, randomized study. *Rev Chir Orthop Reparatrice Appar Mot*. 2001;87:18-28.

5. Stoeckl B, Nogler M, Rosiek R, et al. Navigation improves accuracy of rotational alignment in total knee arthroplasty. *Clin Orthop Relat Res*. 2004;26:180-186.
6. Bolognesi M, Hofmann A. Computer navigation versus standard instrumentation for TKA: a single-surgeon experience. *Clin Orthop Relat Res*. 2005;440:162-169.
7. Amin DV, Kanade T, DiGioia AM III, Jaramaz B. Ultrasound registration of the bone surface for surgical navigation. *Comput Aided Surg*. 2003;8:1-16.
8. Chen TK, Abolmaesumi P, Pichora DR, Ellis RE. A system for ultrasound-guided computer-assisted orthopaedic surgery. *Comput Aided Surg*. 2005;10:281-292.
9. Rosenow JM, Sootsman WK. Application accuracy of an electromagnetic field-based image-guided navigation system. *Stereotact Funct Neurosurg*. 2007;85:75-81.
10. Huitema RB, Hof AL, Postema K. Ultrasonic motion analysis system-measurement of temporal and spatial gait parameters. *J Biomech*. 2002;35:837-842.
11. Khadem R, Yeh CC, Sadeghi-Tehrani M, et al. Comparative tracking error analysis of five different optical tracking systems. *Comput Aided Surg*. 2000;5:98-107.
12. Anderson KC, Buehler KC, Markel DC. Computer assisted navigation in total knee arthroplasty: comparison with conventional methods. *J Arthroplasty*. 2005;20:132-138.
13. Bathis H, Perlick L, Tingart M, et al. Alignment in total knee arthroplasty. A comparison of computer-assisted surgery with the conventional technique. *J Bone Joint Surg Br*. 2004;86:682-687.
14. Jenny JY, Boeri C, Picard F, Leitner F. Reproducibility of intraoperative measurement of the mechanical axes of the lower limb during total knee replacement with a non-image-based navigation system. *Comput Aided Surg*. 2004;9:161-165.
15. Jenny JY, Clemens U, Kohler S, et al. Consistency of implantation of a total knee arthroplasty with a non-image-based navigation system: a case-control study of 235 cases compared with 235 conventionally implanted prostheses. *J Arthroplasty*. 2005;20:832-839.
16. Stiehl JB, Heck DA. Six sigma analysis of computer-assisted surgery tracking protocols in TKA. *Clin Orthop Rel Res*. 2007;464:105-110.
17. Hummel J, Figl M, Birkfelner W, et al. Evaluation of a new electromagnetic tracking system using a standardized assessment protocol. *Phys Med Biol*. 2006;51:N205-N210.
18. Lionberger R. The attraction of electromagnetic computer-assisted navigation in orthopaedic surgery. In: Stiehl JB, Konermann W, Hacker R, eds. Navigation and MIS in Orthopaedic Surgery. Heidelberg, Germany: Springer Verlag; 2006:44-53.
19. Yau WP, Leung A, Chiu KY, et al. Intraobserver errors in obtaining visually selected anatomic landmarks during registration process in nonimage-based navigation-assisted total knee arthroplasty: a cadaveric experiment. *J Arthroplasty*. 2005;20:591-601.
20. Poulin F, Amiot LP. Interference during the use of an electromagnetic tracking system under OR conditions. *J Biomech*. 2002;35(6):733-737.
21. Schicho K, Figl M, Donat M, et al. Stability of miniature electromagnetic tracking systems. *Phy Med Bio*. 2005;50:2089-2098.

SLACK
INCORPORATED
Delivering the best in healthcare information and education worldwide

6900 Grove Road, Thorofare, NJ 08086 USA
phone: 856-848-1000 • fax: 856-848-6091 • www.slackinc.com • www.ORTHOSuperSite.com

Sponsored as an educational service by B. Braun Aesculap